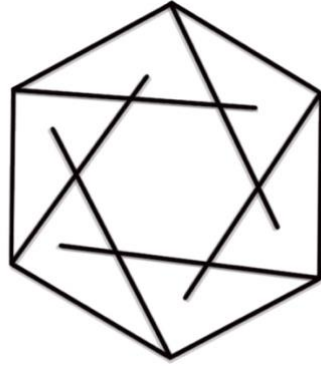

LONDON PROACTIVE MUSCLE MANUAL

www.londonproactive.co.uk

How to use this guide

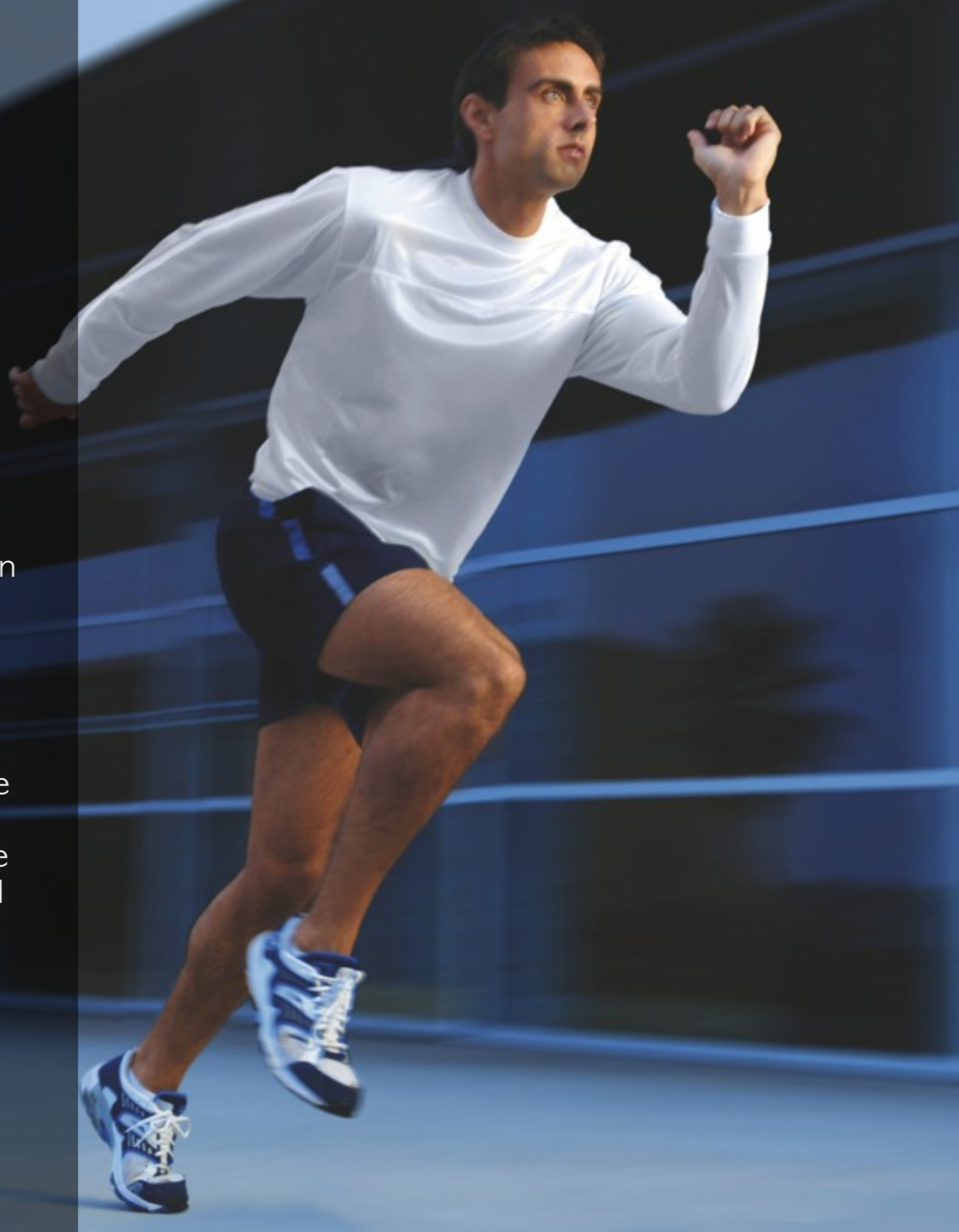This muscle anatomy guide is designed to serve as a learning tool for those studying for fitness-related qualifications. For this purpose, the coloured tabs at the bottom of each page indicate whether the information relates to knowledge requirements for Level 2 (fitness instruction) or Level 3 (personal training). Please note that the knowledge for Level 2 also forms part of the Level 3 requirement. The tabs marked 'Additional knowledge' highlight muscles that are supplementary to Level 2 and 3 knowledge requirements.

The information has been presented in a step by step format that will not only aid revision, but will also support use of the manual during practical workshops. Each individual muscle or muscle group is illustrated with origin and insertion points, as well as relevant bony landmarks, and the accompanying text makes use of the following icons to simplify understanding and aid revision.

Muscles of the lower leg and foot

The muscles of the leg and foot play a key role in the support and locomotion of the human body. These muscles are often divided into four groups: the 'calf' muscles (posterior leg), the peroneals (lateral leg), the ankle/toe extensors (anterior leg), and the ankle/toe flexors (deep posterior leg). At the ankle, the muscles function to dorsiflex (extend) or plantar flex (flex) the foot; in the foot, there are added movements of inversion, eversion and flexion/extension of the toes. The leg muscles that act on the foot are often known as the extrinsic foot muscles whilst the muscles located deeper in the foot are referred to as intrinsic.

Their anatomy is easily studied as most of these muscles are directly accessible to palpation, and with the exception of the popliteus, they all attach to the foot.



Gastrocnemius

Audio: Gastrocnemius



Standing on your toes
Walking uphill, climbing stairs
Pedalling a bike uphill

Daily
Use



Cardio: cycling, walking/
running, stepper, rower
Resistance: calf raise, squat,
lunge, deadlift, step-up,
leg press, leg curl
Power: jumping, hopping
Balance: single leg balance
exercises

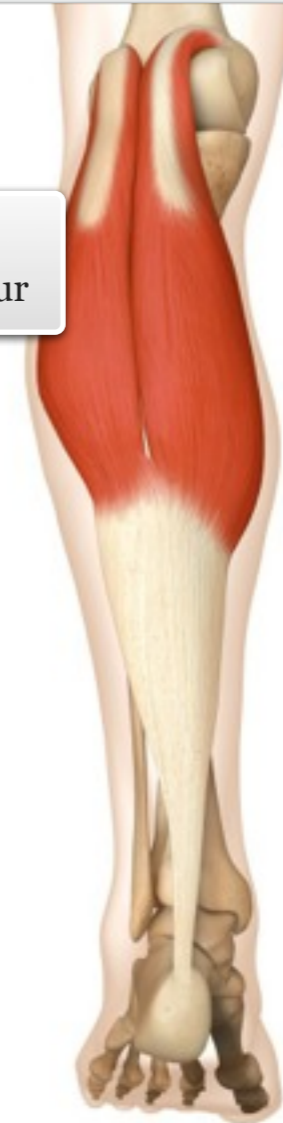Gym

The gastrocnemius is the most superficial muscle of the posterior leg. Comprising of two heads, it crosses both the ankle and knee joints.

MUSCLE ACTIONS: Plantar flexion of the ankle, flexion of the knee

facts

ORIGIN
Posterior, lower femur



INSERTION
Calcaneus (via
calcaneal tendon)

muscle

level || knowledge



Soleus

Audio: Soleus



Standing on your toes
Walking uphill, climbing stairs
Pedalling a bike uphill

Daily
Use

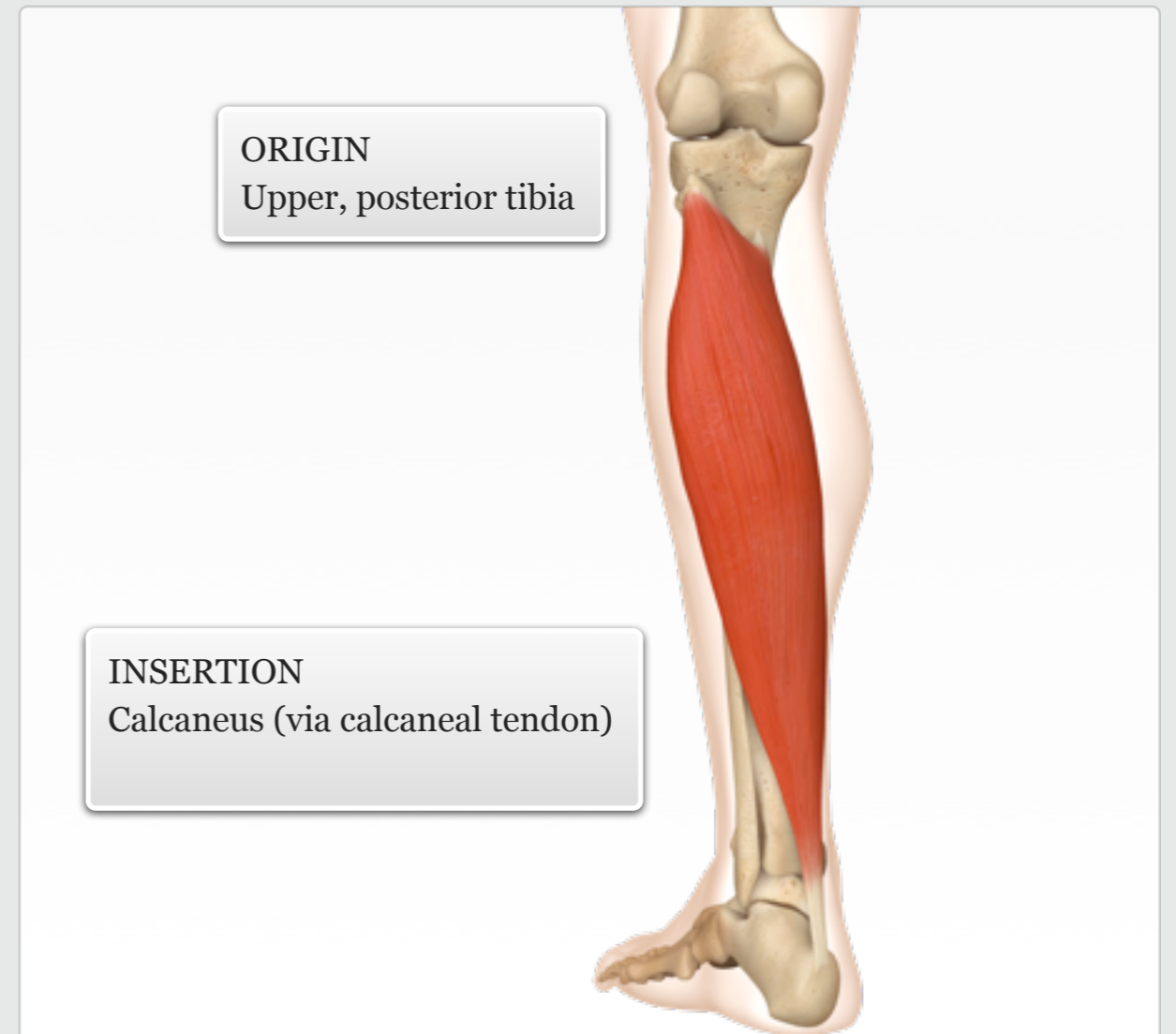


Cardio: cycling, walking/
running, stepper, rower
Resistance: calf raise, squat,
lunge, deadlift, step-up, leg
press, leg cur
Power: jumping, hopping
Balance: single leg balance
exercises

Gym

The thick soleus muscle is deep to the gastrocnemius, however its medial and lateral fibres are clearly palpable and extend further distal than the heads of the gastrocnemius.

MUSCLE ACTIONS: Plantar flexion of the ankle



level || knowledge

facts

muscle



Plantaris

Audio: Plantaris



Standing on your toes
Walking uphill, climbing stairs
Pedalling a bike uphill

Daily
Use



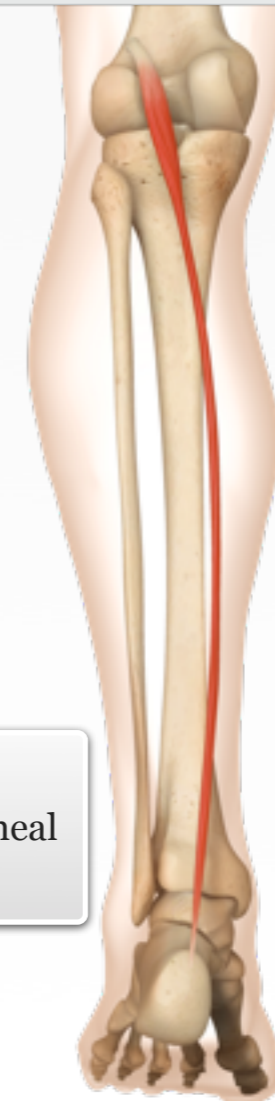Cardio: cycling, walking/
running, stepper, rower
Resistance: calf raise, squat,
lunge, deadlift, step-up, leg
press, leg curl
Power: jumping, hopping
Balance: single leg balance
exercises

Gym

The plantaris is a short muscle that lies at an oblique angle along the posterior knee, yet has the longest tendon in the body which extends down the length of the leg and attaches to the calcaneus. It generally works with the gastrocnemius.

MUSCLE ACTIONS: Weakly plantar flexes the ankle; weakly flexes the knee

facts



ORIGIN
Lateral lower edge of
the femur

INSERTION
Calcaneus (via calcaneal
tendon)

additional + knowledge

muscle



Popliteus

Audio: Popliteus



Running, cycling, swimming
Unlocks the knee during walking/running
Protects lateral meniscus during knee flexion

Daily Use



Cardio: cycling, walking / running
Resistance: leg curl, leg press, squat
Power: jumping, kicking
Balance: single leg squat

Gym

The popliteus is a small muscle located in the popliteal space. Lying beneath the gastrocnemius and plantaris, it is the deepest muscle of the posterior knee.

MUSCLE ACTIONS: Internally rotates the flexed knee, flexes the knee

ORIGIN
Lateral lower edge of the femur

INSERTION
Posterior surface of the tibia

additional + knowledge

facts

muscle



Peroneus longus and brevis

Audio: Peroneus longus and brevis



Scraping mud off inside edge of shoe

Walking/running off-road
Ice skating (end of stroke)

Daily Use



Cardio: walking, running, stepping

Resistance: calf raise, ankle eversion (band)

Power: hopping, jumping, cutting/planting

Balance: single leg balance exercises (stabilisation)

Gym

The peroneus longus and brevis are slender muscles located on the lateral side of the leg, lying between the extensor digitorum longus and the soleus. Their distal tendons are palpable along the side of the heel and behind the lateral malleolus.

MUSCLE ACTIONS: Evert the foot, plantar flex the ankle

facts

ORIGIN

Head of fibula, and lateral surface of fibula

Peroneus longus

Peroneus brevis

INSERTION

Base of first metatarsal and medial cuneiform (longus);
tuberosity of fifth metatarsal (brevis)

muscle

additional + knowledge



Tibialis anterior

Audio: Tibialis anterior



Putting on and taking off socks/shoes

Lifting foot during swing phase of gait

Daily Use



Cardio: walking, running, cycling (with cleats)

Resistance: standing/lying ankle dorsiflexion (band)

Power: hopping, jumping (landing), cutting/planting

Balance: single leg balance exercises (stabilisation)

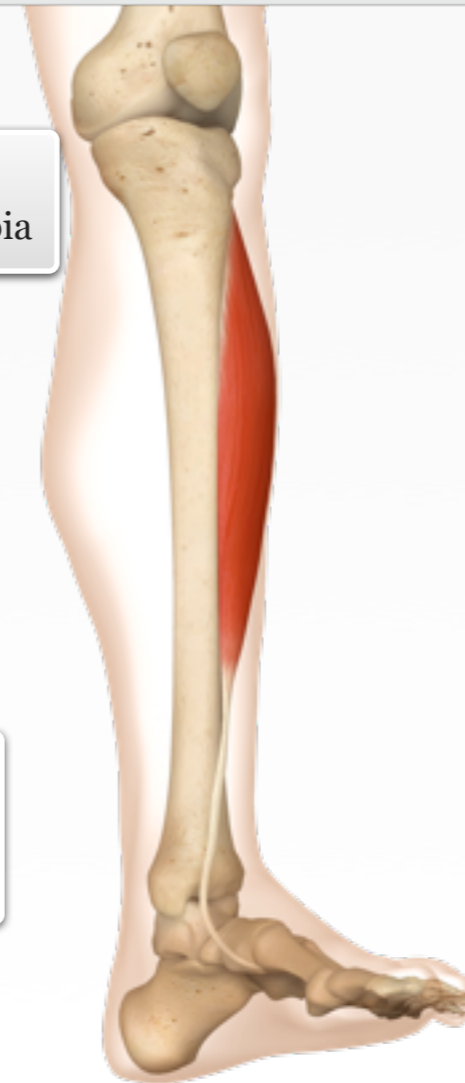Gym

The tibialis anterior is a large superficial muscle, and the most visible of the extensors of the ankle and toes. It lies against the lateral surface of the tibia.

MUSCLE ACTIONS: Dorsiflexion and inversion of the ankle

ORIGIN
Lateral, upper tibia

INSERTION
First metatarsal and medial tarsal



level || knowledge

facts

muscle



Extensor digitorum longus

Audio: Extensor digitorum longus



Putting on and taking off socks/shoes

Lifting foot during swing phase of gait

Walking barefoot on hot sand

Daily Use



Cardio: walking, running, cycling (with cleats)

Resistance: standing/lying ankle dorsiflexion (band)

Power: hopping, jumping (landing), cutting/planting

Balance: single leg balance exercises (stabilisation)

Gym

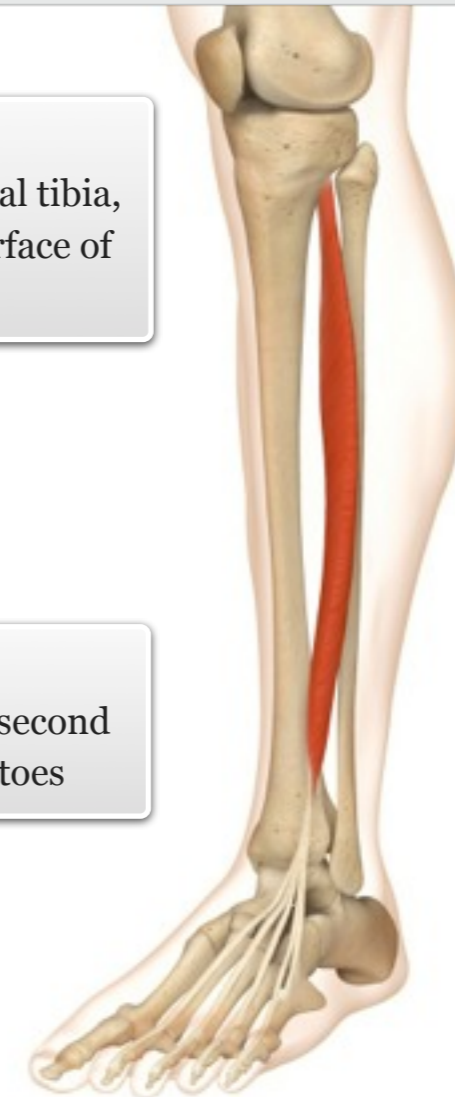
The extensor digitorum longus is partially superficial and lies between the tibialis anterior and the peroneals. Its four tendons are clearly palpable on the dorsal surface of the foot.

MUSCLE ACTIONS: Everts the foot; dorsiflexes the ankle; extends second through fifth toes

facts

ORIGIN
Upper lateral tibia, anterior surface of fibula

INSERTION
Phalanges of second through fifth toes



muscle

additional + knowledge



Extensor hallucis longus

Audio: Extensor hallucis longus



Putting on and taking off socks/shoes

Lifting foot during swing phase of gait

Walking barefoot on hot sand

Daily Use



Cardio: walking, running, cycling (with cleats)

Resistance: standing/lying ankle dorsiflexion (band)

Power: hopping, jumping (landing), cutting/planting

Balance: single leg balance exercises (stabilisation)

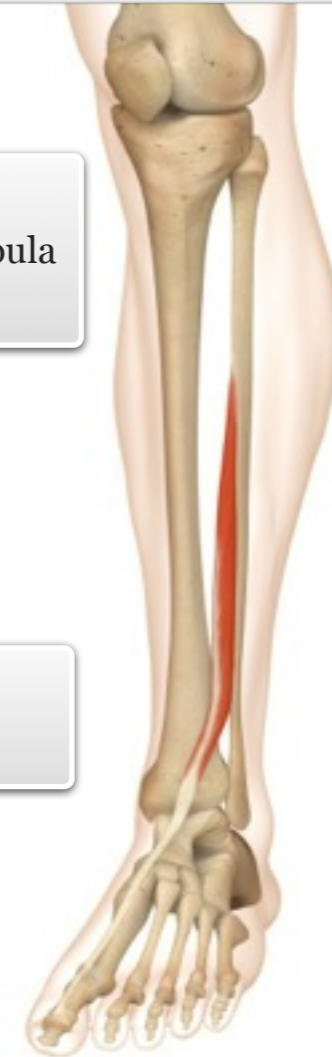Gym

The extensor hallucis longus lies deep to the anterior tibialis and the extensor digitorum longus, and is not directly palpable; however, its distal tendon can be palpated on the dorsal surface of the foot.

MUSCLE ACTIONS: Inverts the foot; dorsiflexes the ankle; extends the first toe

ORIGIN
Anterior surface of fibula

INSERTION
First toe



additional + knowledge

facts

muscle



Flexor hallucis longus

Audio: Flexor hallucis longus



Walking on tip-toes
Walking on uneven surfaces
Turning the bath tap on/off
with your toes

Daily
Use



Cardio: walking, running
Resistance: toe gripping
exercises
Power: hopping, jumping,
cutting/planting
Balance: single leg balance
exercises (stabilisation)

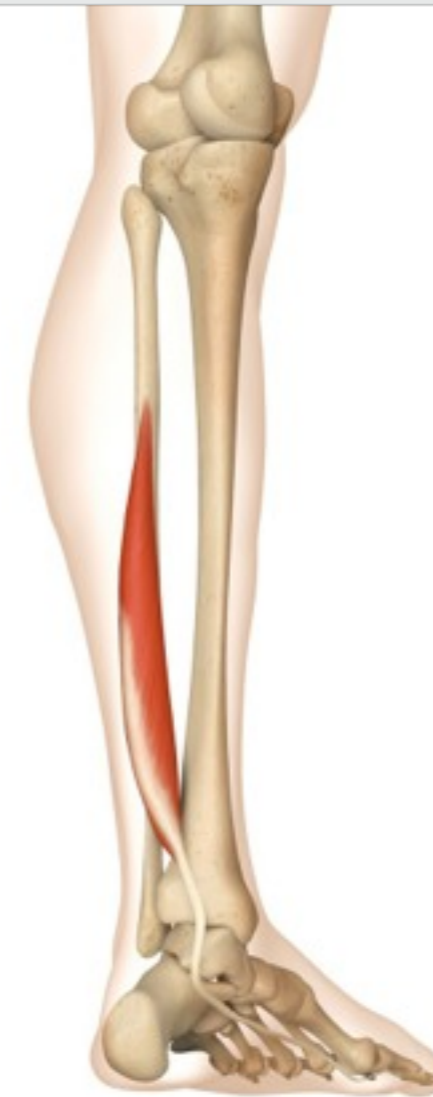Gym

The flexor hallucis longus is one of three slender muscles of the posterior compartment of the leg. The muscle arises from the inferior fibular surface and its fibres pass obliquely downward and backward, helping to support the longitudinal arch of the foot.

MUSCLE ACTIONS: Flexes the first toe, inverts the foot, weakly plantar flexes the ankle

facts

ORIGIN
Middle half of
posterior fibula



INSERTION
First toe

muscle

additional + knowledge



Tibialis posterior

Audio: Tibialis posterior



Pushing down on car pedals
Walking on uneven surfaces

Daily
Use



Cardio: walking, running
Resistance: bent knee and
seated calf raises
Power: hopping, jumping,
cutting/planting
Balance: single leg balance
exercises (stabilisation)

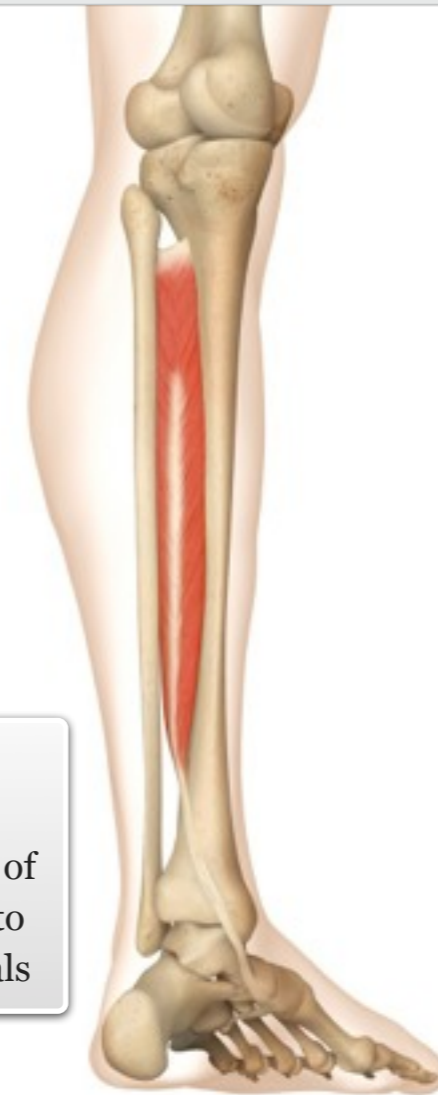Gym

The tibialis posterior is the most central of the muscles of the posterior compartment of the leg. It is also the deepest of all the calf muscles and helps support the arch of the foot.

MUSCLE ACTIONS: Inverts the foot;
plantar flexes the ankle

ORIGIN
Posterior
surface of
tibia and
fibula

INSERTION
All five tarsal
bones and bases of
second through to
fourth metatarsals



additional + knowledge

facts

muscle



Flexor digitorum longus

Audio: Flexor digitorum longus



Walking on uneven surfaces,
particularly barefoot
Turning the bath tap on/off
with your toes

Daily
Use



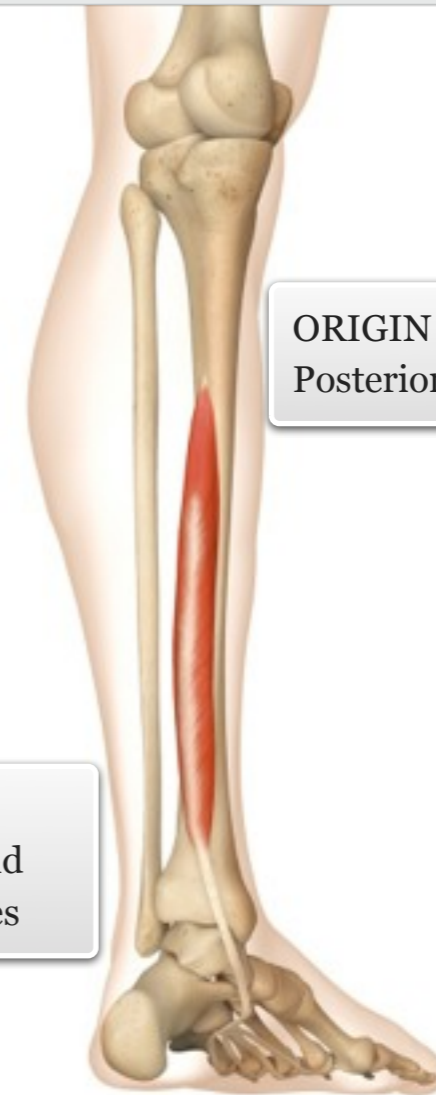Cardio: walking, running
Resistance: bent knee and
seated calf raises
Power: hopping, jumping,
cutting/planting
Balance: single leg balance
exercises (stabilisation)

Gym

The flexor digitorum longus is situated on the tibial side of the leg. Its fibres pass obliquely forward and lateral, ending in a tendon that passes behind the medial malleolus and under the foot.

MUSCLE ACTIONS: Flexes the second through to fifth toes; weakly plantar flexes the ankle; inverts the foot

ORIGIN
Posterior surface of tibia



INSERTION
Phalanges of second
through to fifth toes

additional + knowledge

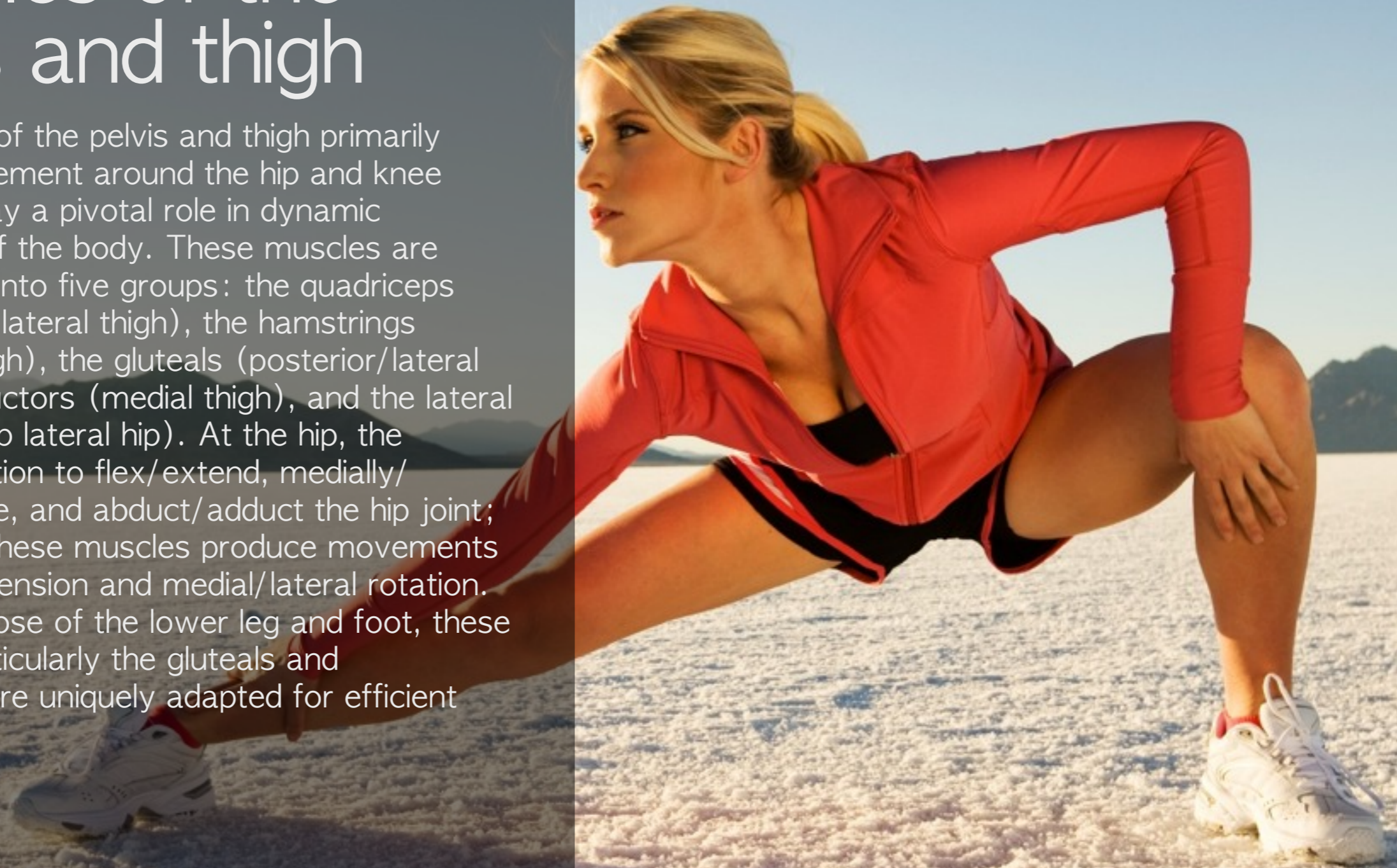facts

muscle



Muscles of the pelvis and thigh

The muscles of the pelvis and thigh primarily produce movement around the hip and knee joints, and play a pivotal role in dynamic stabilisation of the body. These muscles are often divided into five groups: the quadriceps (anterior and lateral thigh), the hamstrings (posterior thigh), the gluteals (posterior/lateral hip), the adductors (medial thigh), and the lateral rotators (deep lateral hip). At the hip, the muscles function to flex/extend, medially/laterally rotate, and abduct/adduct the hip joint; at the knee, these muscles produce movements of flexion/extension and medial/lateral rotation. Along with those of the lower leg and foot, these muscles (particularly the gluteals and quadriceps) are uniquely adapted for efficient bipedal gait.



Quadriceps group

Audio: Quadriceps group



Standing up from a sitting position

Stepping up onto a curb

Kicking a ball

Stabilisation of the knee during squatting and bending

Daily Use



N/A

Gym

Rectus femoris
Vastus intermedius
Vastus medialis
Vastus lateralis

The four large muscles of the quadriceps primarily extend the knee and originate from the pelvis and upper end of the thigh, converging into a single tendon just above the knee.

The superficial rectus femoris, located on the anterior thigh, is the only muscle that crosses the hip and knee; vastus intermedius is deep to the rectus femoris. The vastus medialis forms a 'teardrop' shape at the distal end of the medial thigh, while the vastus lateralis runs along the lateral thigh.

MUSCLE ACTIONS: Extension of the knee, flexion of the hip

facts

ORIGIN
Ilium and femur

AIIS

Rectus femoris

Vastus lateralis

Vastus medialis

Patella

INSERTION
Tibia

Tibial tuberosity

muscle

level || knowledge



Rectus femoris

Audio: Rectus femoris



Standing up from a sitting position
Stepping up onto a curb
Kicking a ball
Stabilisation of the knee during squatting and bending

Daily Use



Cardio: cycling, walking/running, stepper, rower, cross trainer
Resistance: leg press, knee extension, squat/deadlift/lunge/step up variations
Power: jumping, hopping
Balance: single leg exercise variations

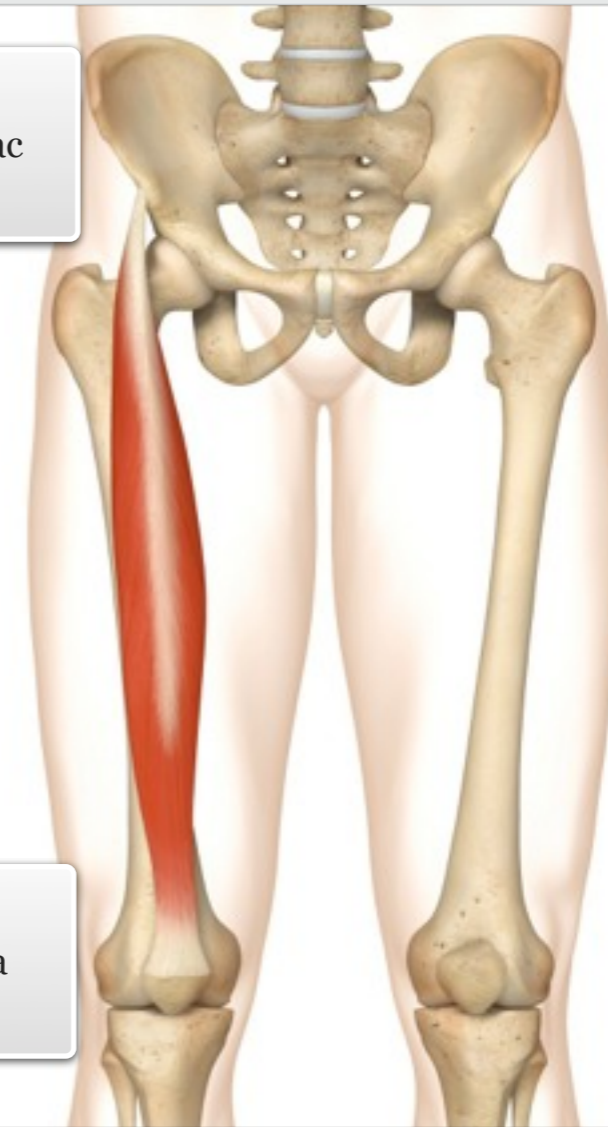
Gym

MUSCLE ACTIONS: Flexion of the hip and extension of the knee

facts

ORIGIN
Anterior inferior iliac spine (AIIS)

INSERTION
Anterior, upper tibia via the patella



muscle

level ||| knowledge



Vastus intermedius

Audio: Vastus intermedius



Standing up from a sitting position
Stepping up onto a curb
Kicking a ball
Stabilisation of the knee during squatting and bending

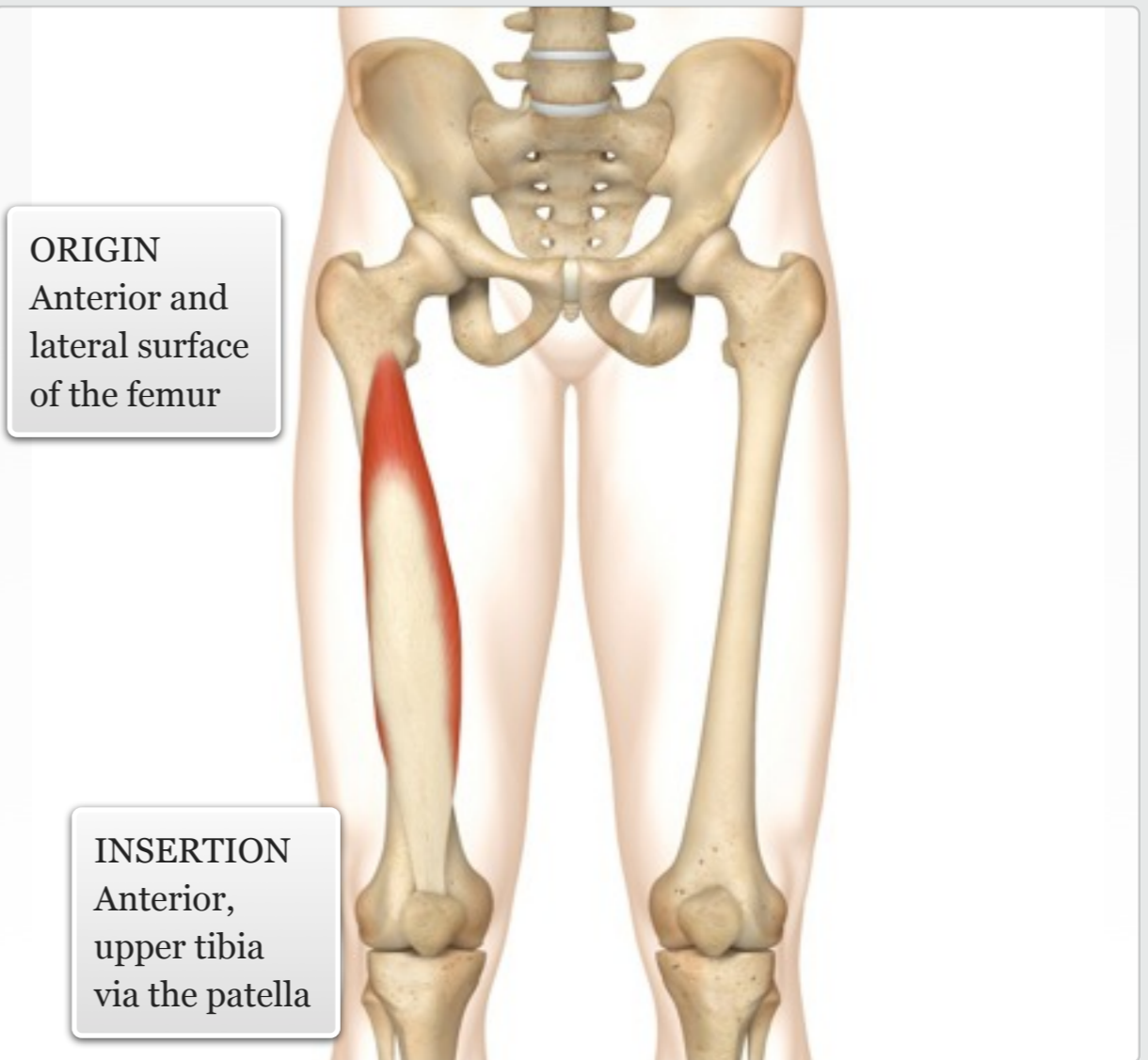
Daily Use



Cardio: cycling, walking/running, stepper, rower, cross trainer
Resistance: leg press, knee extension, squat/deadlift/lunge/step up variations
Power: jumping, hopping
Balance: single leg exercise variations

Gym

MUSCLE ACTIONS: Extension of the knee



level ||| knowledge

facts

muscle



Vastus medialis

Audio: Vastus medialis



Standing up from a sitting position
Stepping up onto a curb
Kicking a ball
Stabilisation of the knee during squatting and bending

Daily Use



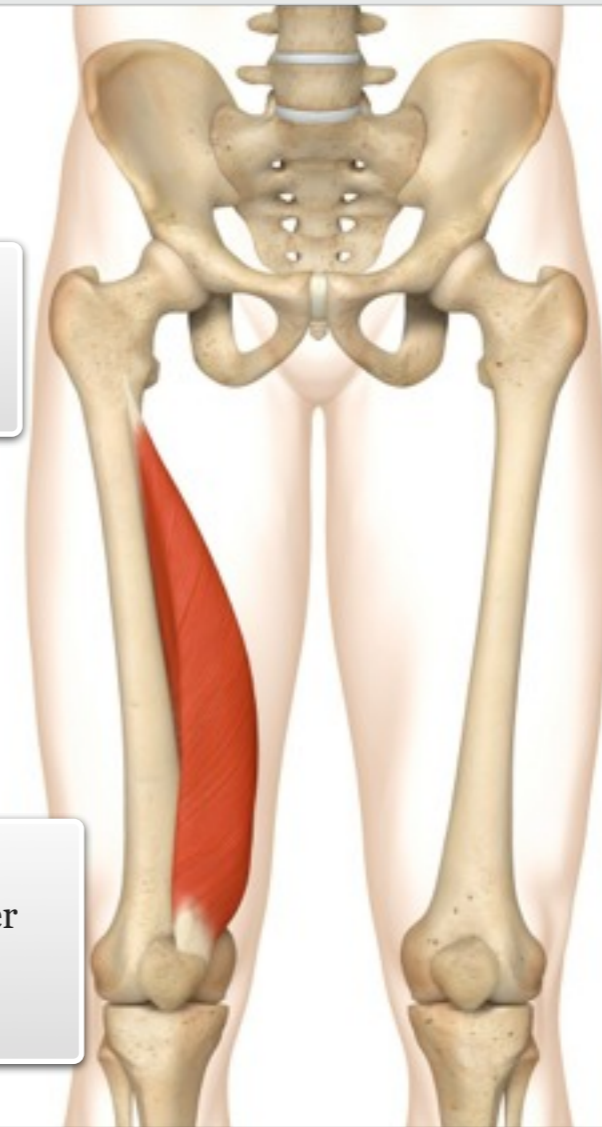Cardio: cycling, walking/running, stepper, rower, cross trainer
Resistance: leg press, knee extension, squat/deadlift/lunge/step up variations
Power: jumping, hopping
Balance: single leg exercise variations

Gym

MUSCLE ACTIONS: Extension of the knee

ORIGIN
Medial surface of the femur

INSERTION
Anterior, upper tibia via the patella



level ||| knowledge

facts

muscle



Vastus lateralis

Audio: Vastus lateralis



Standing up from a sitting position

Stepping up onto a curb

Kicking a ball

Stabilisation of the knee during squatting and bending

Daily Use



Cardio: cycling, walking/running, stepper, rower, cross trainer

Resistance: leg press, knee extension, squat/deadlift/lunge/step up variations

Power: jumping, hopping

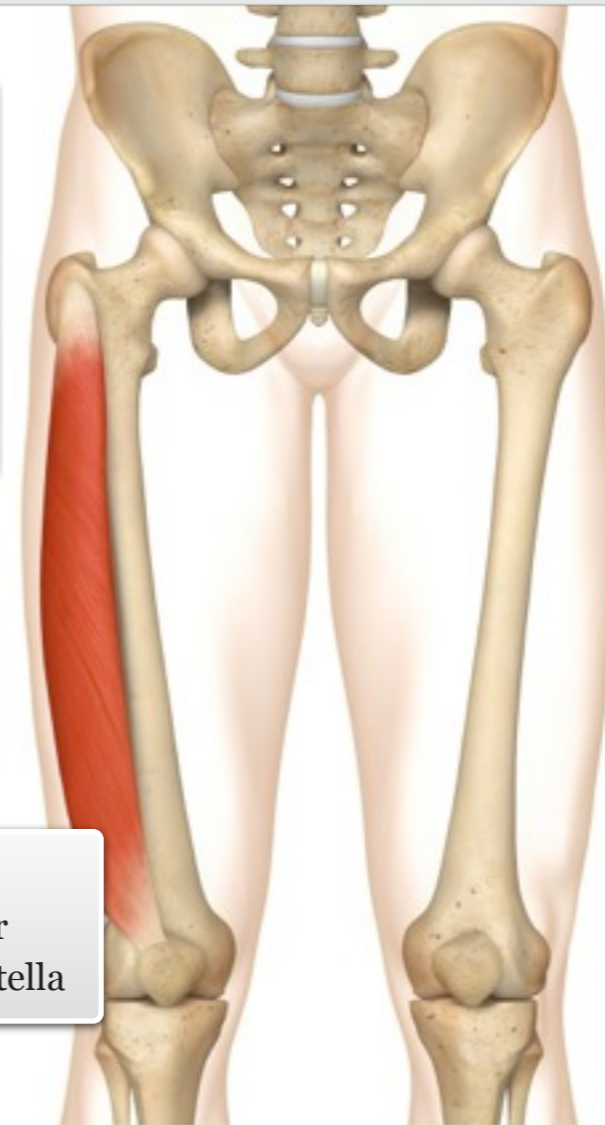
Balance: single leg exercise variations

Gym

MUSCLE ACTIONS: Extension of the knee

ORIGIN
Greater trochanter and lateral surface of the femur

INSERTION
Anterior, upper tibia via the patella



level ||| knowledge

facts

muscle



Hamstrings group

Audio: Hamstrings group



Running, cycling, swimming
Climbing stairs
Stabilisation of the hip when bending
Wiping feet on a doormat

Daily Use



N/A

Gym

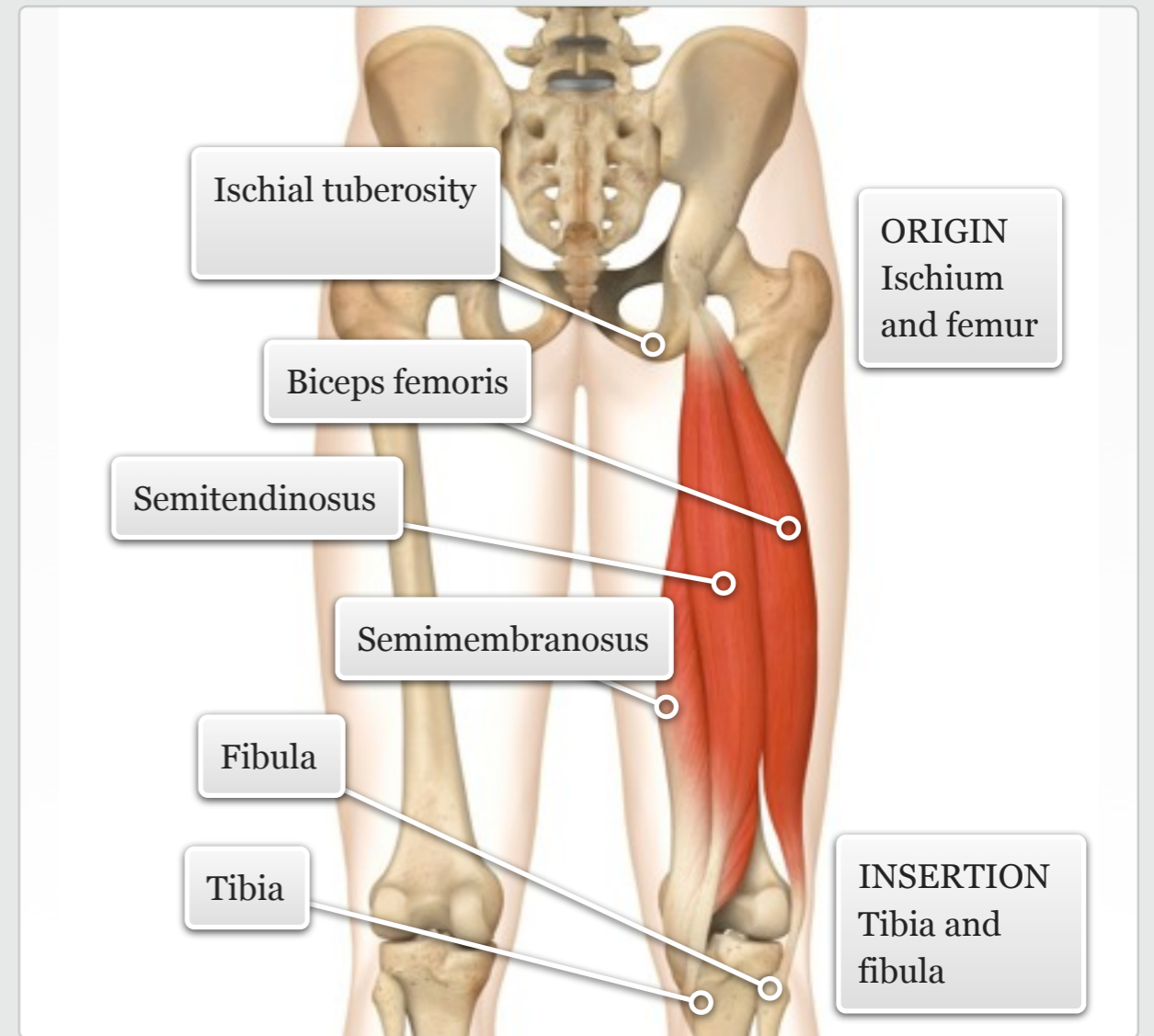
Biceps femoris
Semitendinosus
Semimembranosus

The hamstrings are located along the posterior thigh and are not as big as the quadriceps they are nevertheless strong hip extensors and knee flexors. All three hamstring muscles have a common origin at the ischium, and their tendons are easily palpable.

The biceps femoris is the most lateral of the hamstrings and has two heads – a superficial long head and a deeper short head. The semitendinosus lies superficial to the deeper semimembranosus, both of which are located more medially on the posterior thigh.

MUSCLE ACTIONS: Extension of hip and flexion of knee

facts



muscle

level || knowledge

Biceps femoris

Audio: Biceps femoris



Running, cycling, swimming
Climbing stairs
Stabilisation of the hip when bending
Wiping feet on a doormat

Daily
Use



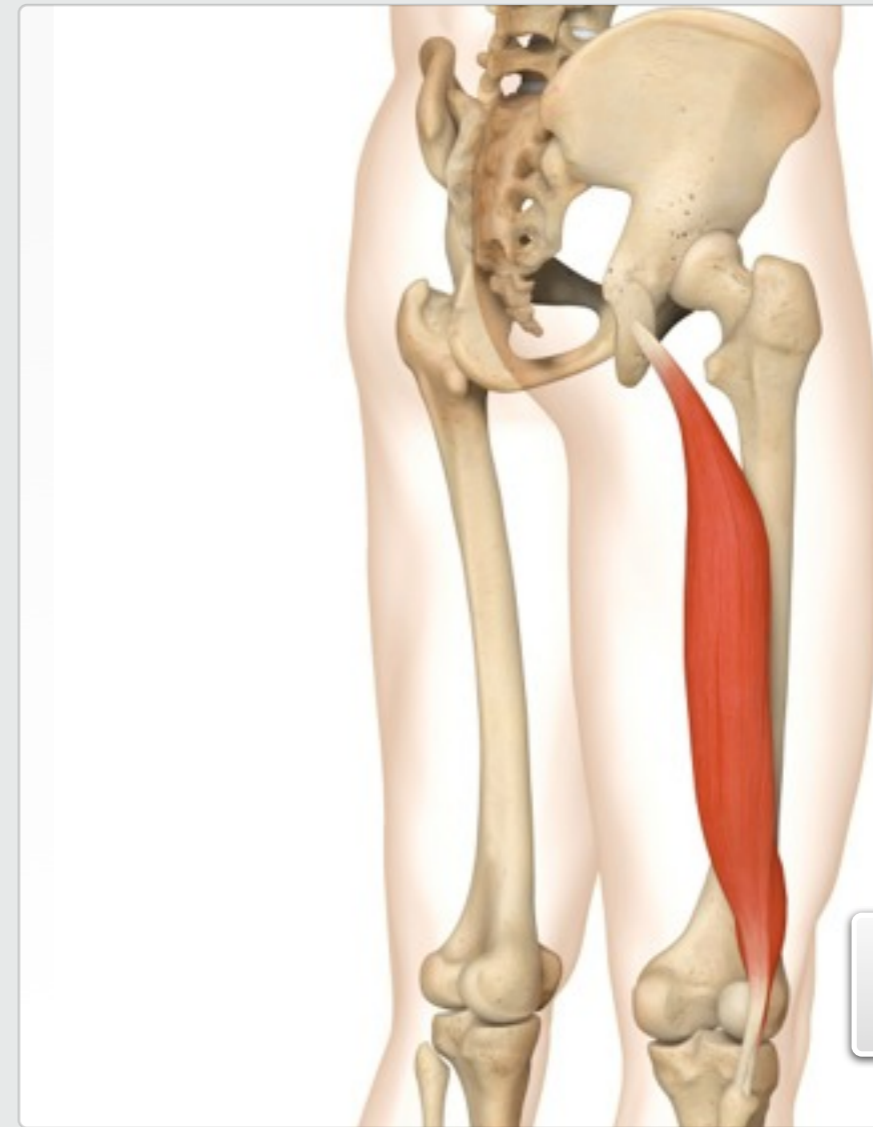
Cardio: running, stepper, cross trainer
Resistance: leg curl, leg press, squat/deadlift/lunge/step up variations
Power: jumping, hopping
Balance: single leg squat/deadlift

Gym

level ||| knowledge

MUSCLE ACTIONS: Extension and external rotation of the hip. Flexion of the knee

facts



ORIGIN
Ischial tuberosity and posterior surface of the femur

INSERTION
Head of the fibula

muscle



Semitendinosus

Audio: Semitendinosus



Running, cycling, swimming
Climbing stairs
Stabilisation of the hip when bending
Wiping feet on a doormat

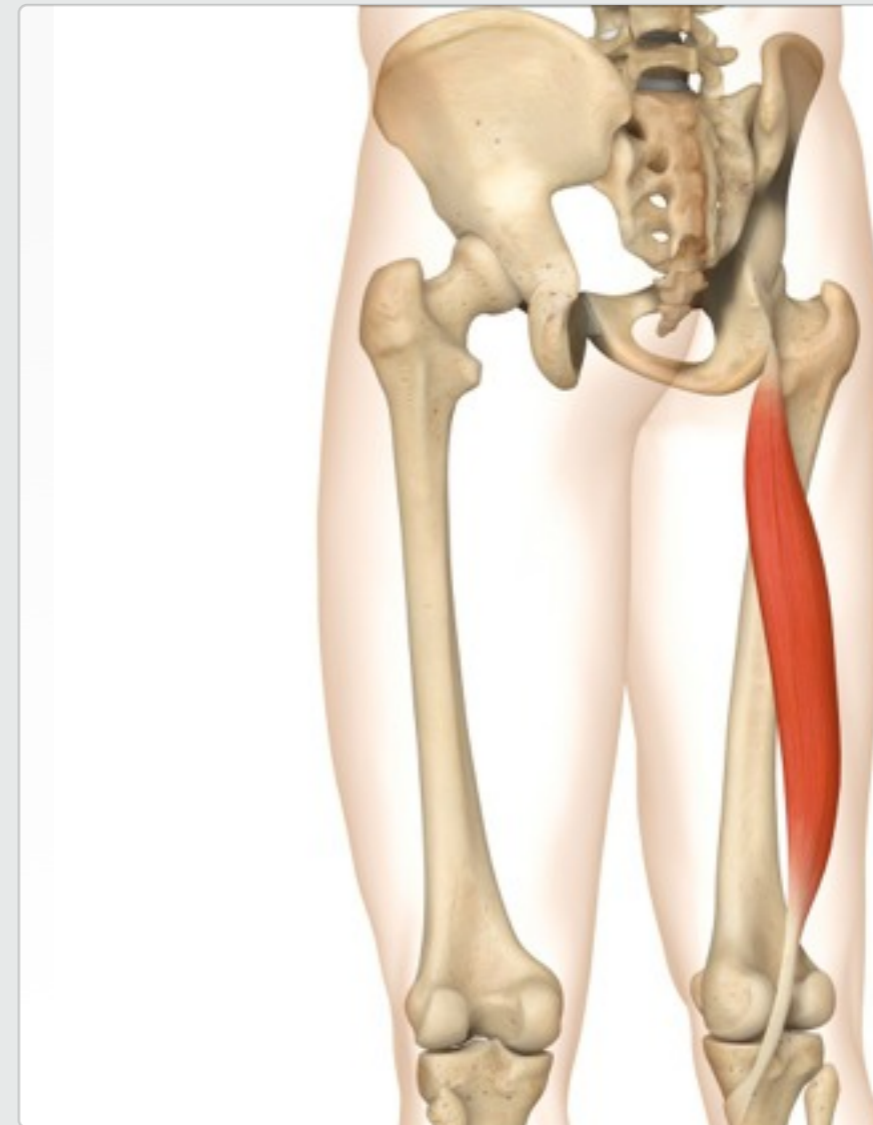Daily Use



Cardio: running, stepper, cross trainer
Resistance: leg curl, leg press, squat/deadlift/lunge/step up variations
Power: jumping, hopping
Balance: single leg squat/deadlift

Gym

MUSCLE ACTIONS: Extension of the hip. Flexion of the knee, posteriorly tilts the pelvis



ORIGIN
Ischial tuberosity

INSERTION
Upper medial surface of the tibia

level ||| knowledge

facts

muscle



Semimembranosus

Audio: Semimembranosus



Running, cycling, swimming
Climbing stairs
Stabilisation of the hip when bending
Wiping feet on a doormat

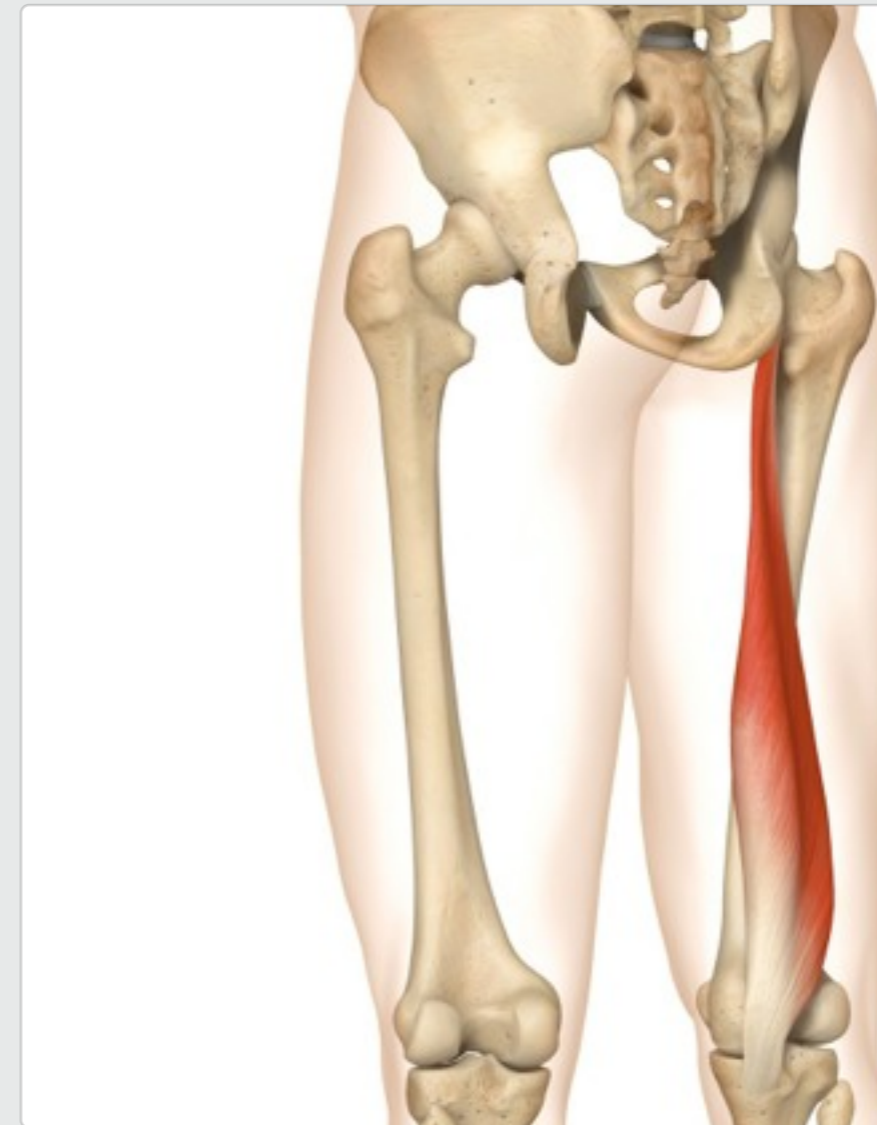Daily
Use



Cardio: running, stepper, cross trainer
Resistance: leg curl, leg press, squat/deadlift/lunge/step up variations
Power: jumping, hopping
Balance: single leg squat/deadlift

Gym

MUSCLE ACTIONS: Extension of the hip. Flexion of the knee, posteriorly tilts the pelvis



ORIGIN
Ischial
tuberosity

INSERTION
Upper medial
surface of the
tibia

level ||| knowledge

facts

muscle



Gluteals

Audio: Gluteals



Running, cycling, swimming,
skating, dancing
Climbing stairs
Stabilisation of the hip when
bending

Daily
Use



N/A

Gym

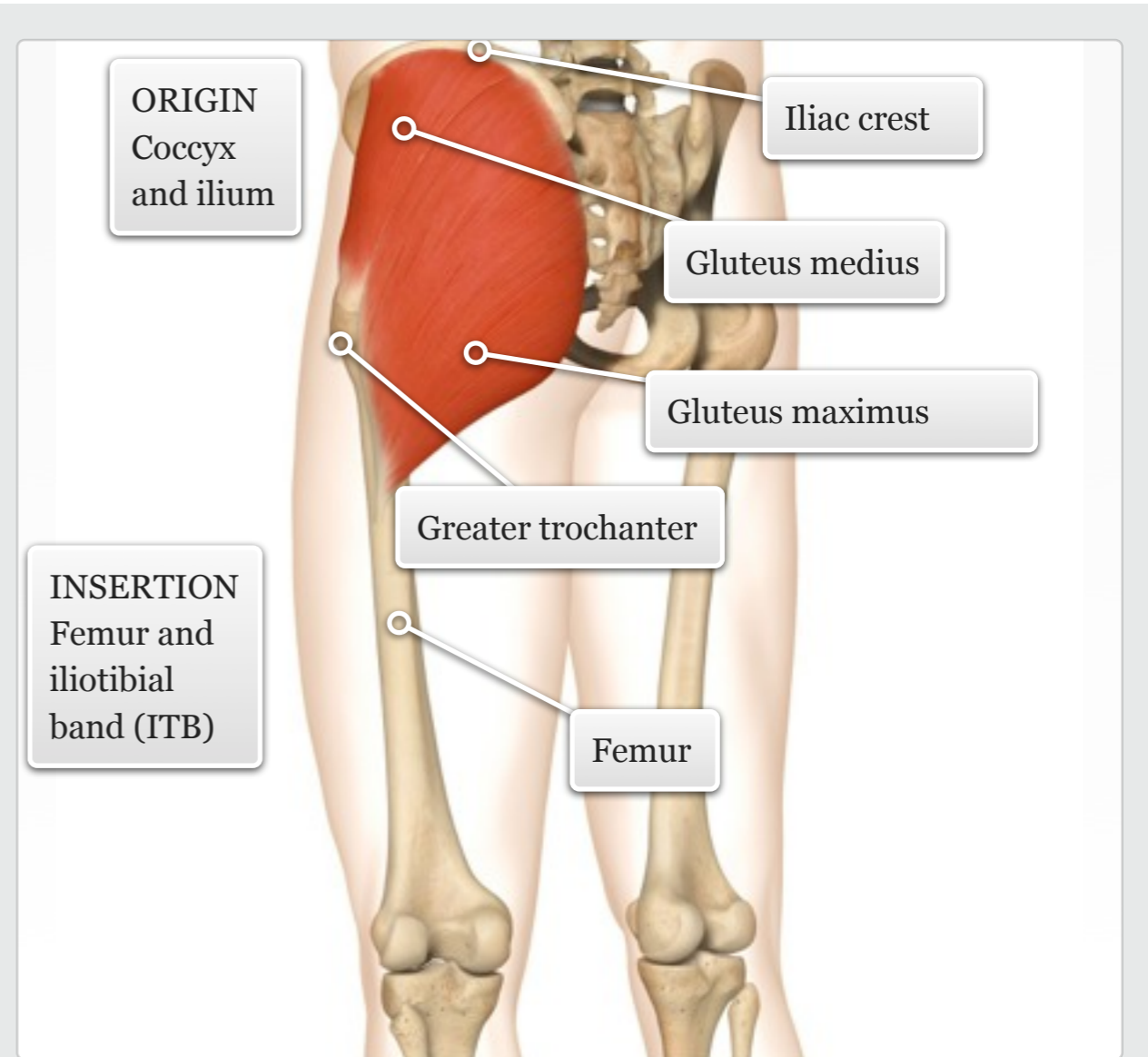
Gluteus maximus
Gluteus medius
Gluteus minimus

The three gluteal muscles are located on the posterior aspect of the ilium, deep to the surrounding adipose tissue.

The large gluteus maximus is the most posterior and superficial of the three, and runs diagonally across the buttock; the gluteus medius lies on the lateral side of the hip. Both the gluteus maximus and medius are powerful extensors and abductors of the hip. The gluteus minimus (not shown) lies deep to the gluteus medius and flexes and medially rotates the hip.

MUSCLE ACTIONS: Extension, external rotation and abduction of the hip

facts



muscle

level || knowledge



Gluteus maximus

Audio: Gluteus maximus



Running, cycling, swimming,
skating, dancing
Climbing stairs
Stabilisation of the hip when
bending

Daily
Use



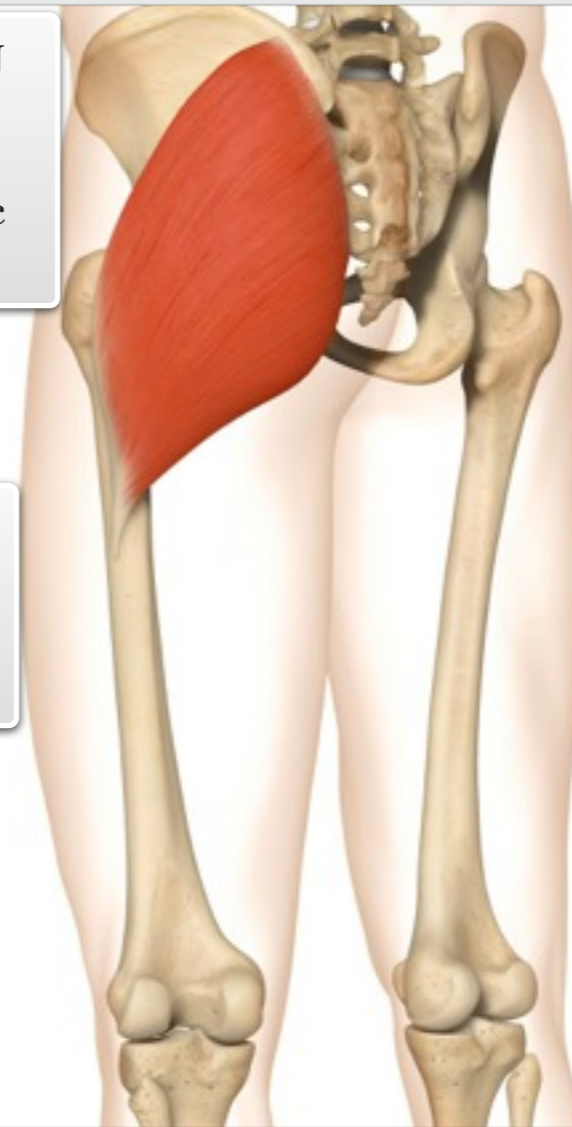
Cardio: running, stepper,
cross trainer, rower
Resistance: leg press, leg
curl, squat, deadlift, lunge,
step up, standing/lying hip
extension
Power: jumping, hopping
Balance: single leg exercise
variations

Gym

MUSCLE ACTIONS: Extension,
abduction and external rotation of the
hip

ORIGIN
Coccyx,
sacrum
and iliac
crest

INSERTION
Upper femur
and iliotibial
band (ITB)



level || knowledge

facts

muscle



Gluteus medius

Audio: Gluteus medius



Running, cycling, swimming,
skating, dancing
Climbing stairs
Stabilisation of the hip when
bending

Daily
Use



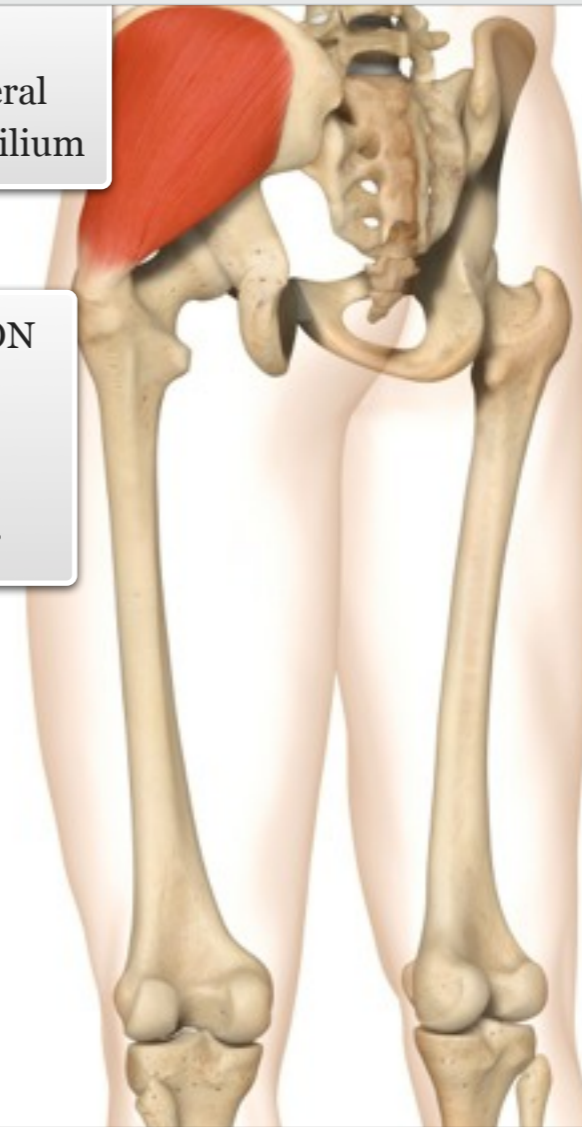
Cardio: running, stepper,
cross trainer, rower
Resistance: leg press, leg
curl, side lunge, standing/lying
abduction
Power: jumping, hopping,
cutting/planting
Balance: single leg exercise
variations

Gym

MUSCLE ACTIONS: Abduction and
internal rotation of hip (anterior fibres) ;
extension and external rotation of hip
(posterior fibres)

ORIGIN
Upper lateral
surface of ilium

INSERTION
Lateral
surface of
greater
trochanter



level ||| knowledge

facts

muscle



Gluteus minimus

Audio: Gluteus minimus



Running, cycling, swimming,
skating, dancing
Climbing stairs
Stabilisation of the hip when
bending

Daily
Use



Cardio: running, stepper,
cross trainer, rower
Resistance: leg press, leg
curl, side lunge, standing/lying
abduction, wood chopping
Power: jumping, hopping,
cutting/planting
Balance: single leg exercise
variations

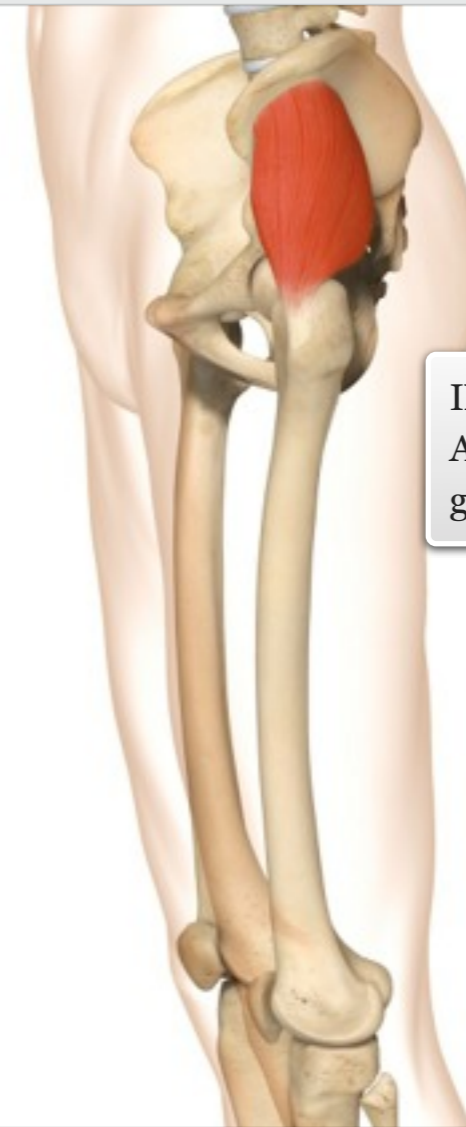
Gym

MUSCLE ACTIONS: Abduction and
internal rotation of the hip

facts

level ||| knowledge

muscle



ORIGIN
Lateral
surface of
the ilium

INSERTION
Anterior surface of
greater trochanter



Hip adductor group

Audio: Hip adductor group



Wood chopping
Ice skating (during turning)
Horse riding (gripping with thighs)
Stabilising the pelvis/hip during walking/running and bending

Daily Use



N/A

Gym

Adductor magnus
Adductor longus
Adductor brevis
Pectineus
Gracilis

The five adductors are located along the medial thigh between the quadriceps and hamstrings. Of the five muscles, the pectineus and adductor longus are the most anterior; lying behind them is the adductor brevis, and the most posterior is the adductor magnus (anterior to the hamstrings). These four muscles are positioned posterior to the quadriceps. The fifth adductor, gracilis, lies on the medial thigh, and is the only adductor that crosses the knee joint.

MUSCLE ACTIONS: Adduction of the hip

facts

ORIGIN
Pubis and ischium

Superior pubis

Pectineus

Adductor brevis

Adductor longus

Adductor magnus

Gracilis

INSERTION
Femur

Medial femoral condyle

muscle

level || knowledge



Adductor magnus

Audio: Adductor magnus



Wood chopping
Ice skating (during turning)
Horse riding (gripping with thighs)
Stabilising the pelvis/hip during walking/running and bending

Daily Use



Cardio: running, cycling, stepper, rower, swimming
Resistance: lying/standing/seated hip adduction; wood chop variations; stabilisation during squatting and lunging
Power: jumping, hopping, kicking
Balance: stabilisation during single leg exercises

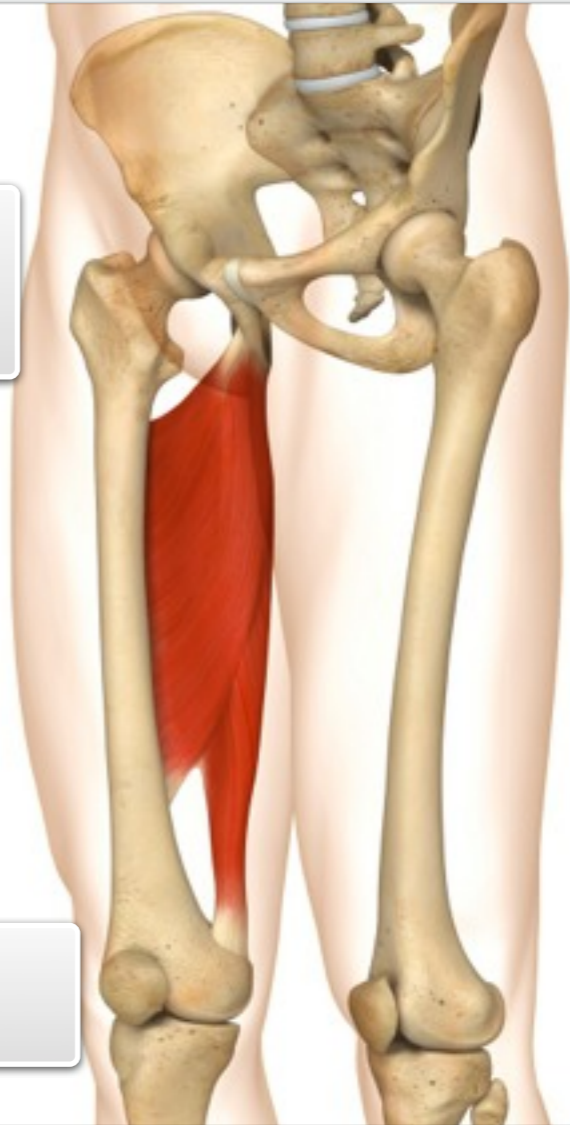Gym

MUSCLE ACTIONS: Adduction, internal rotation and extension of the hip

facts

ORIGIN
Base of the pubis, and ischium

INSERTION
Mid to lower femur



muscle

level ||| knowledge



Adductor longus

Audio: Adductor longus



Wood chopping
Ice skating (during turning)
Horse riding (gripping with thighs)
Stabilising the pelvis/hip during walking/running and bending

Daily Use



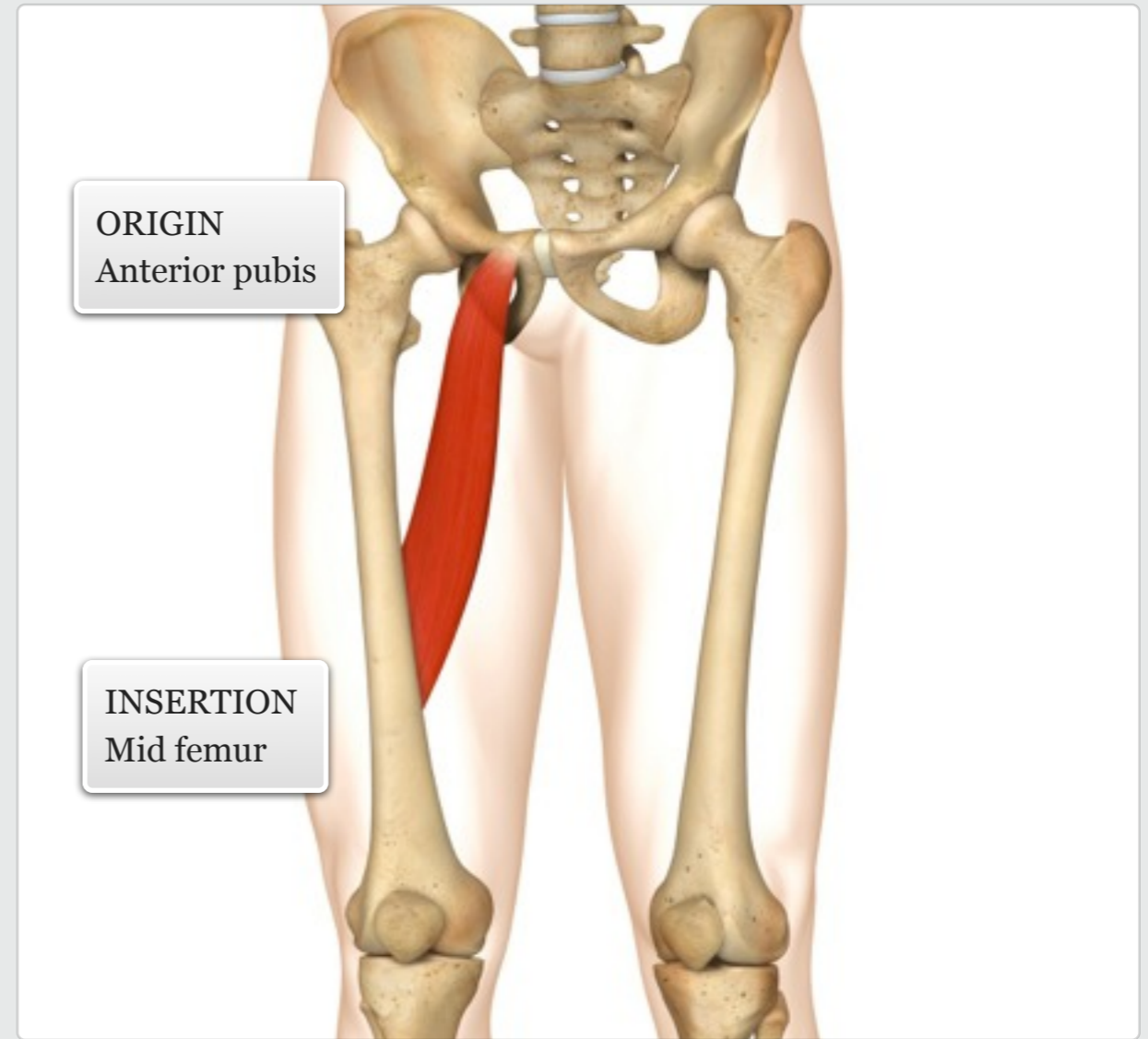
Cardio: running, cycling, stepper, rower, swimming
Resistance: lying/standing/seated hip adduction; wood chop variations; stabilisation during squatting and lunging
Power: jumping, hopping, kicking
Balance: stabilisation during single leg exercises

Gym

MUSCLE ACTIONS: Adduction and internal rotation of the hip

ORIGIN
Anterior pubis

INSERTION
Mid femur



level ||| knowledge

facts

muscle



Adductor brevis

Audio: Adductor brevis



Wood chopping
Ice skating (during turning)
Horse riding (gripping with thighs)
Stabilising the pelvis/hip during walking/running and bending

Daily
Use



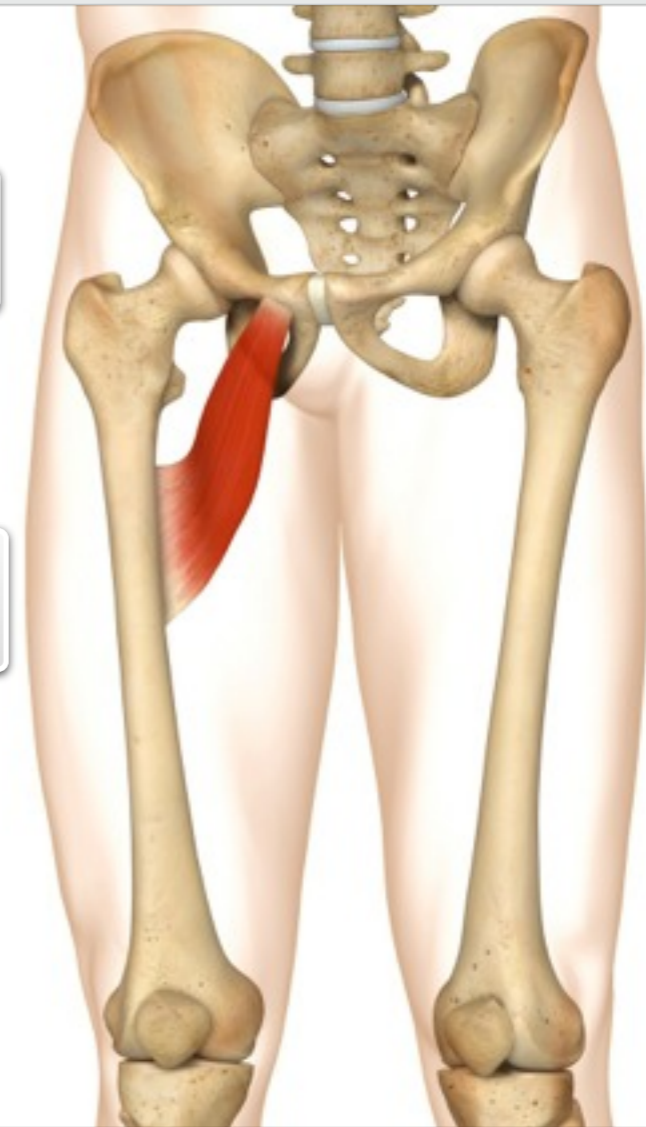
Cardio: running, cycling, stepper, rower, swimming
Resistance: lying/standing/seated hip adduction; wood chop variations; stabilisation during squatting and lunging
Power: jumping, hopping, kicking
Balance: stabilisation during single leg exercises

Gym

MUSCLE ACTIONS: Adduction and internal rotation of the hip

ORIGIN
Anterior pubis

INSERTION
Upper femur



level ||| knowledge

facts

muscle



Pectineus

Audio: Pectineus



Wood chopping
Ice skating (during turning)
Horse riding (gripping with thighs)
Stabilising the pelvis/hip during walking/running and bending

Daily Use



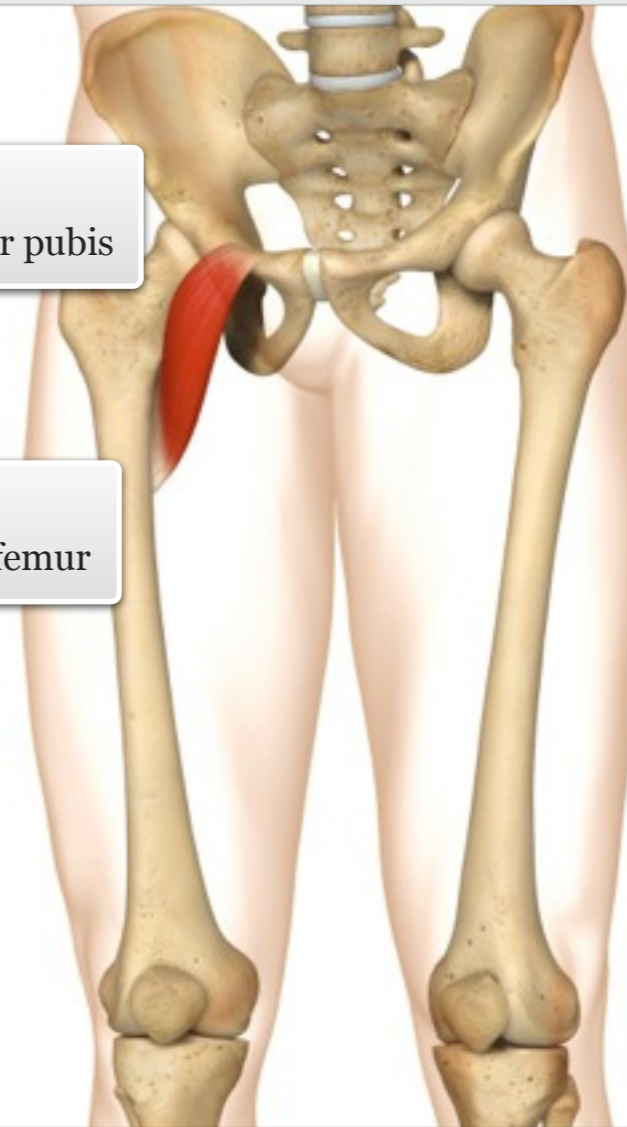
Cardio: running, cycling, stepper, rower, swimming
Resistance: lying/standing/seated hip adduction; wood chop variations; stabilisation during squatting and lunging
Power: jumping, hopping, kicking
Balance: stabilisation during single leg exercises

Gym

MUSCLE ACTIONS: Adduction and flexion of the hip

ORIGIN
Anterior, superior pubis

INSERTION
Posterior, upper femur



level ||| knowledge

facts

muscle



Gracilis

Audio: Gracilis



Wood chopping
Ice skating (during turning)
Horse riding (gripping with thighs)
Stabilising the pelvis/hip during walking/running and bending

Daily
Use



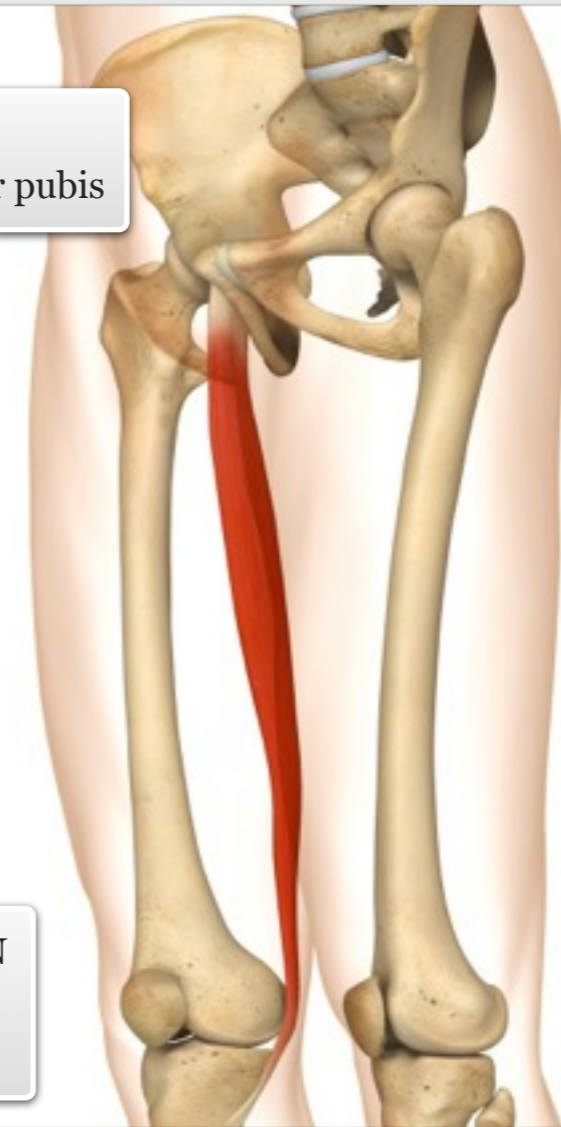
Cardio: running, cycling, stepper, rower, swimming
Resistance: lying/standing/seated hip adduction; wood chop variations; leg curl; side lunge
Power: jumping, hopping, kicking
Balance: stabilisation during single leg exercises

Gym

MUSCLE ACTIONS: Adduction and internal rotation of the hip, flexion of the knee

ORIGIN
Anterior, inferior pubis

INSERTION
Medial, upper tibia



level ||| knowledge

facts

muscle



Hip Flexors

Audio: Hip Flexors



Walking uphill, climbing, hiking
Getting out of bed/up off the floor (sit-up type movement)

Daily Use



N/A

Gym

Iliacus

Psoas major

The iliacus and psoas major are collectively known as the iliopsoas, and are important hip flexors and stabilisers of the low back. Butchers will often refer to these muscles as 'tenderloin'.

The long psoas major muscle is located deep to the abdominal viscera, and stretches from the lumbar vertebrae to the lesser trochanter. The shorter, bulkier iliacus also runs deep to the abdominal contents, originating at the iliac fossa.

MUSCLE ACTIONS: Flexion of the hip

level || knowledge

facts

ORIGIN
Ilium and lumbar vertebrae

Psoas major

Iliacus

Iliac crest

Lesser trochanter

INSERTION
Lesser trochanter

muscle



Iliacus

Audio: Iliacus



Walking uphill, climbing, hiking
Getting out of bed/up off the floor (sit-up type movement)

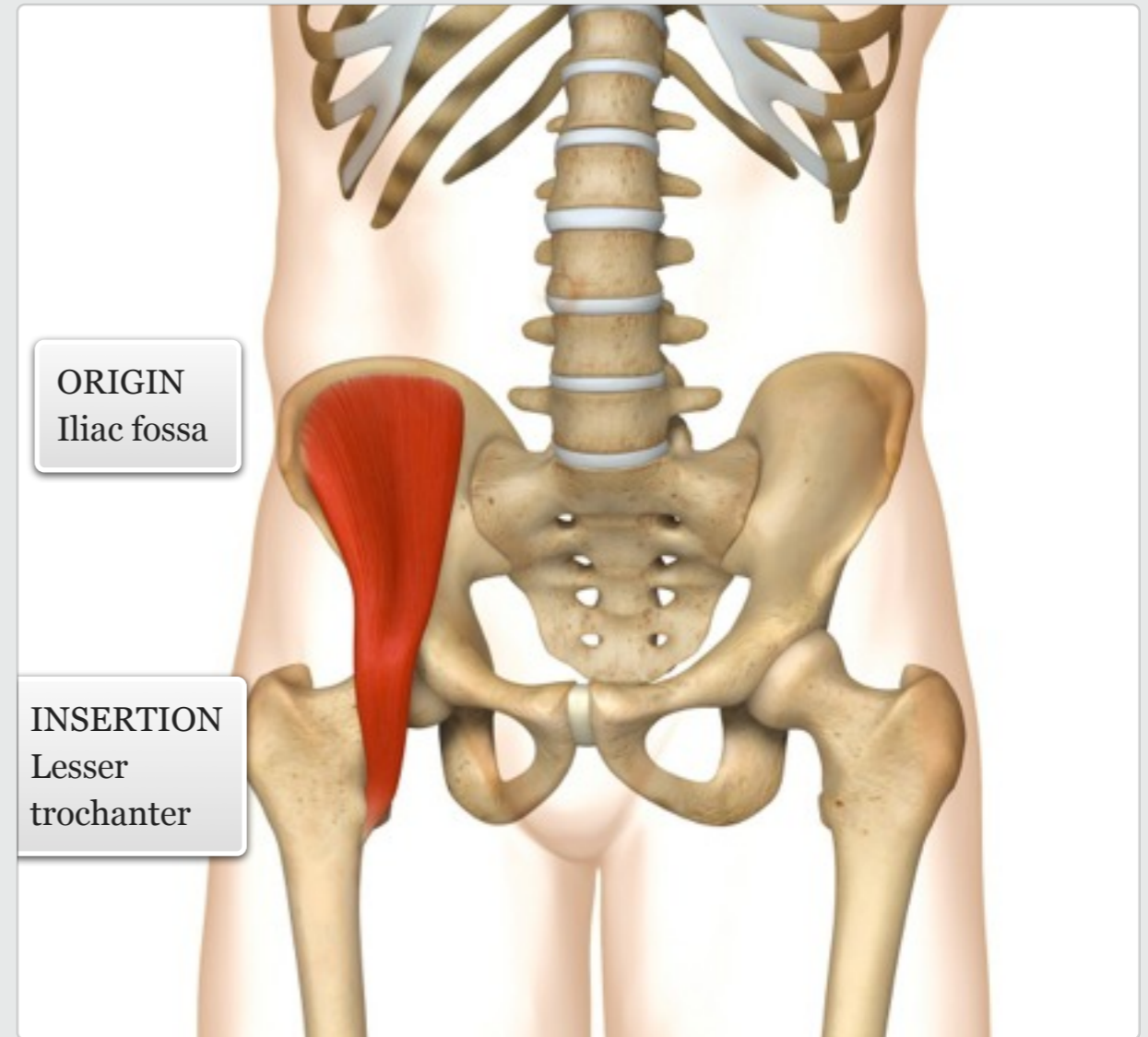
Daily
Use



Cardio: running, cycling, stepper
Resistance: lying/standing/hanging leg raises; jack-knife on stability ball; plank variations
Power: tuck jumps, front kicks
Balance: single leg exercises that involve hip flexion

Gym

MUSCLE ACTIONS: Flexion and external rotation of the hip



level ||| knowledge

facts

muscle



Psoas major

Audio: Psoas major



Walking uphill, climbing, hiking
Getting out of bed/up off the floor (sit-up type movement)

Daily Use



Cardio: running, cycling, stepper
Resistance: lying/standing/hanging leg raises; jack-knife on stability ball; plank variations
Power: tuck jumps, front kicks
Balance: single leg exercises that involve hip flexion

Gym

MUSCLE ACTIONS: Flexes and externally rotates the hip, laterally flexes the spine, anteriorly tilts the pelvis when the femur is fixed

ORIGIN
Transverse processes of T12-L5

INSERTION
Lesser trochanter

level ||| knowledge

facts

muscle



Tensor fasciae latae and iliotibial tract

Audio: Tensor fasciae latae and iliotibial tract



Raising legs to climb into a car

Daily Use



Cardio: running, cycling
Resistance: squatting
Power: jumping, kicking (to side)
Balance: single leg balance reach

Gym

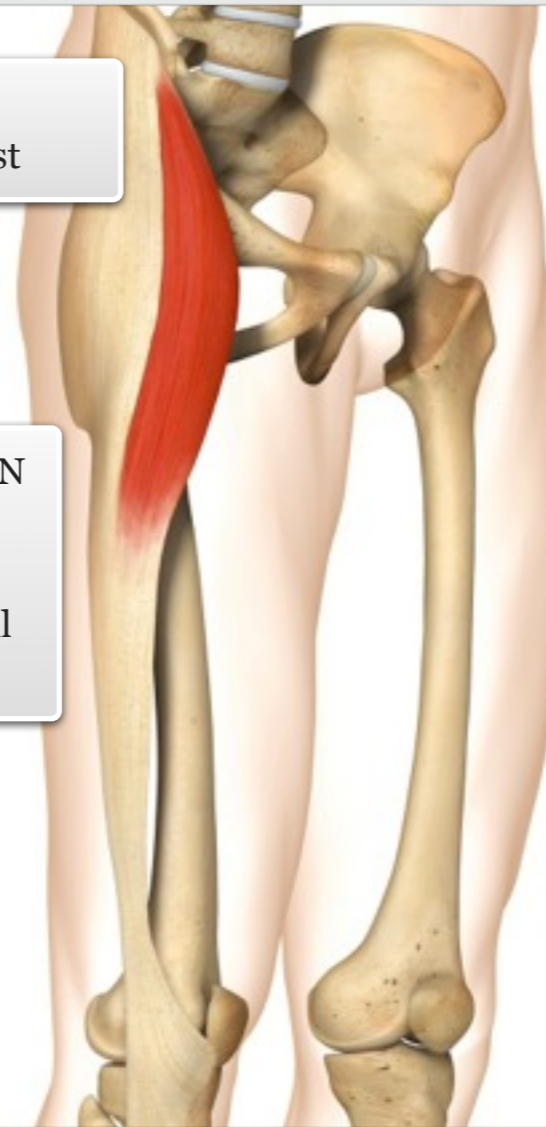The tensor fasciae latae (TFL) is a small, superficial muscle located on the lateral side of the upper thigh, and attaches to the iliotibial tract along with the gluteus maximus. The iliotibial tract is a superficial sheet of fascia running along the lateral thigh, emerging from the gluteal fascia and inserting at the tibial tubercle. It is considered to be a strong stabilising component of the hip and knee.

MUSCLE ACTIONS: Flexion and abduction of the hip

facts

ORIGIN
Anterior iliac crest

INSERTION
Lateral upper tibia via iliotibial band (ITB)



muscle

level ||| knowledge



Sartorius

Audio: Sartorius



Sitting on the floor in a tailor/
lotus position
Crossing/uncrossing legs

Daily
Use



Cardio: cycling, walking/
running, stepper
Resistance: leg raise
variations, sit-ups (feet
secured); stability ball jack-
knife
Power: jumping

Gym

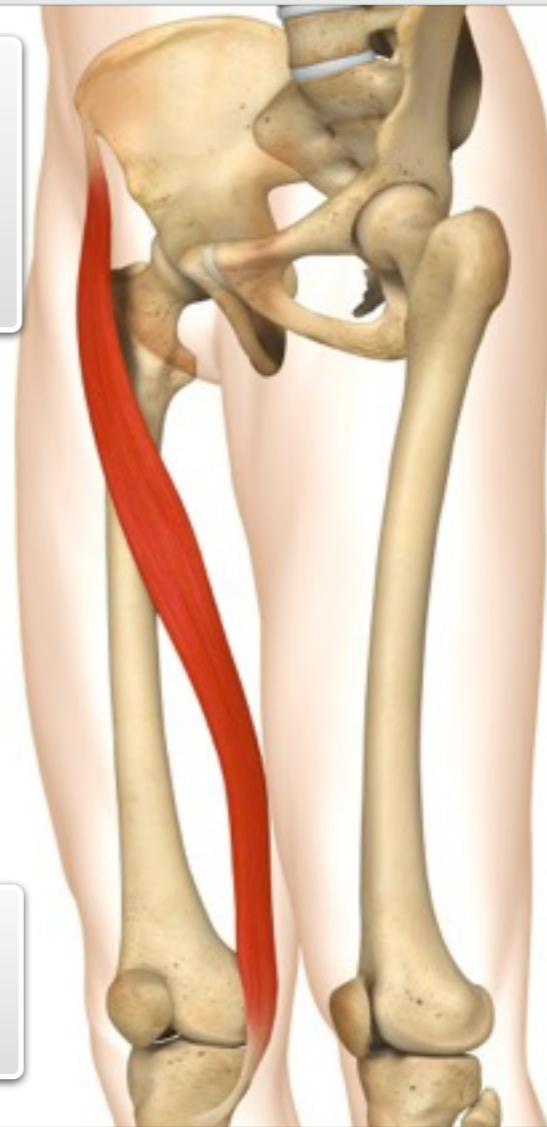The sartorius is the longest muscle in the body, extending from the anterior superior iliac spine (ASIS), across the front of the thigh, to the medial aspect of the knee.

MUSCLE ACTIONS: Flexion, abduction and external rotation of the hip, flexion and internal rotation of the knee.

facts

ORIGIN
Anterior
superior
iliac spine
(ASIS)

INSERTION
Medial
upper tibia



muscle

level ||| knowledge



Piriformis

Audio: Piriformis



Stabilisation of pelvis during standing
Controlling rapid hip medial rotation during gait

Daily Use



Cardio: cycling, walking/running, stepper
Resistance: stabilisation during squat, lunge, deadlift, step-up, leg press
Power: jumping, hopping
Balance: single leg balance exercises

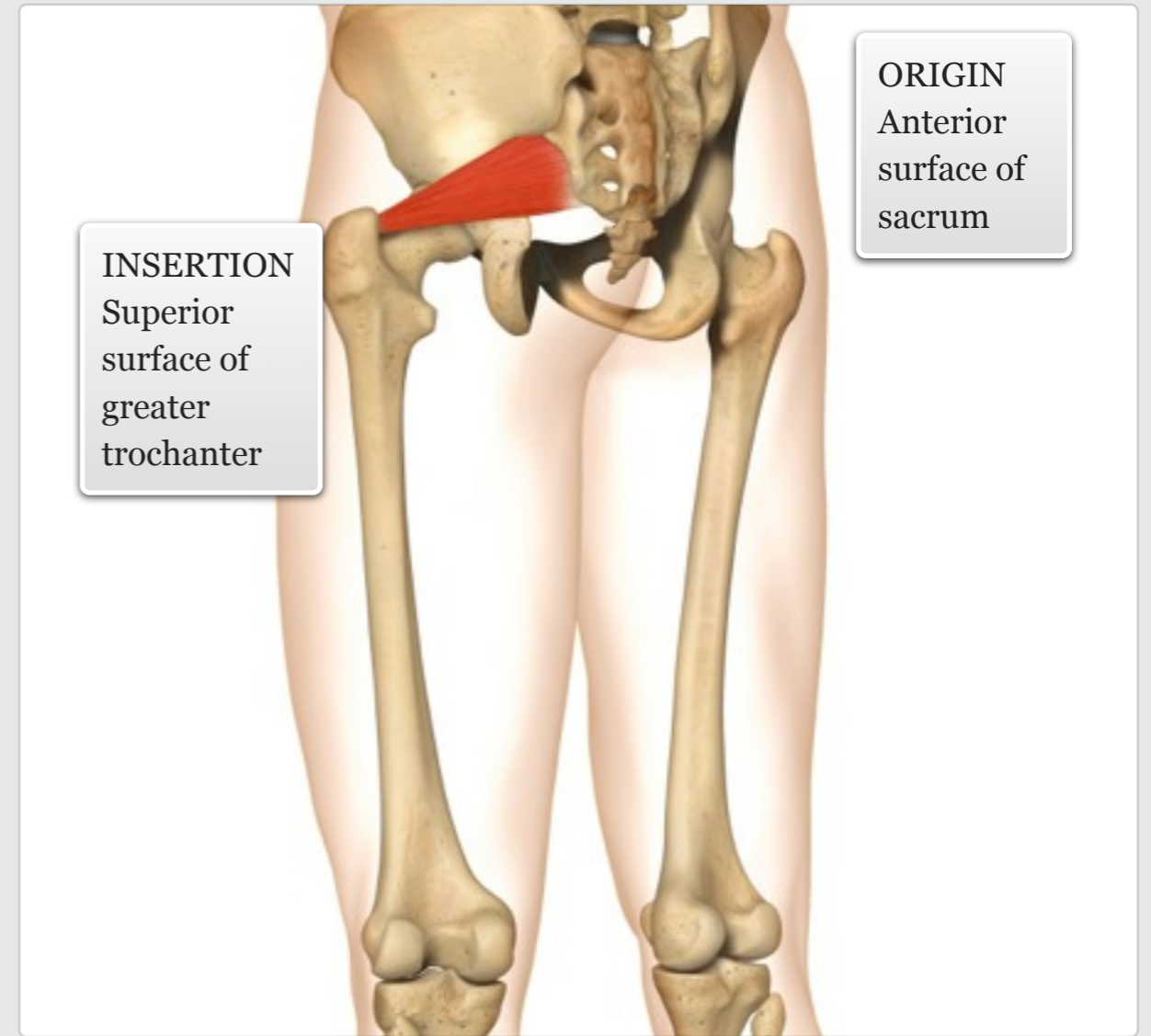
Gym

level ||| knowledge

The piriformis is a flat muscle that lies superficial to the sciatic nerve and deep to the gluteus maximus. It is one of six deep lateral rotators of the hip.

MUSCLE ACTIONS: Abduction and external rotation of the hip.

facts



muscle



Quadratus femoris

Audio: Quadratus femoris



Stabilisation of pelvis during standing
Controlling rapid hip medial rotation during gait

Daily Use



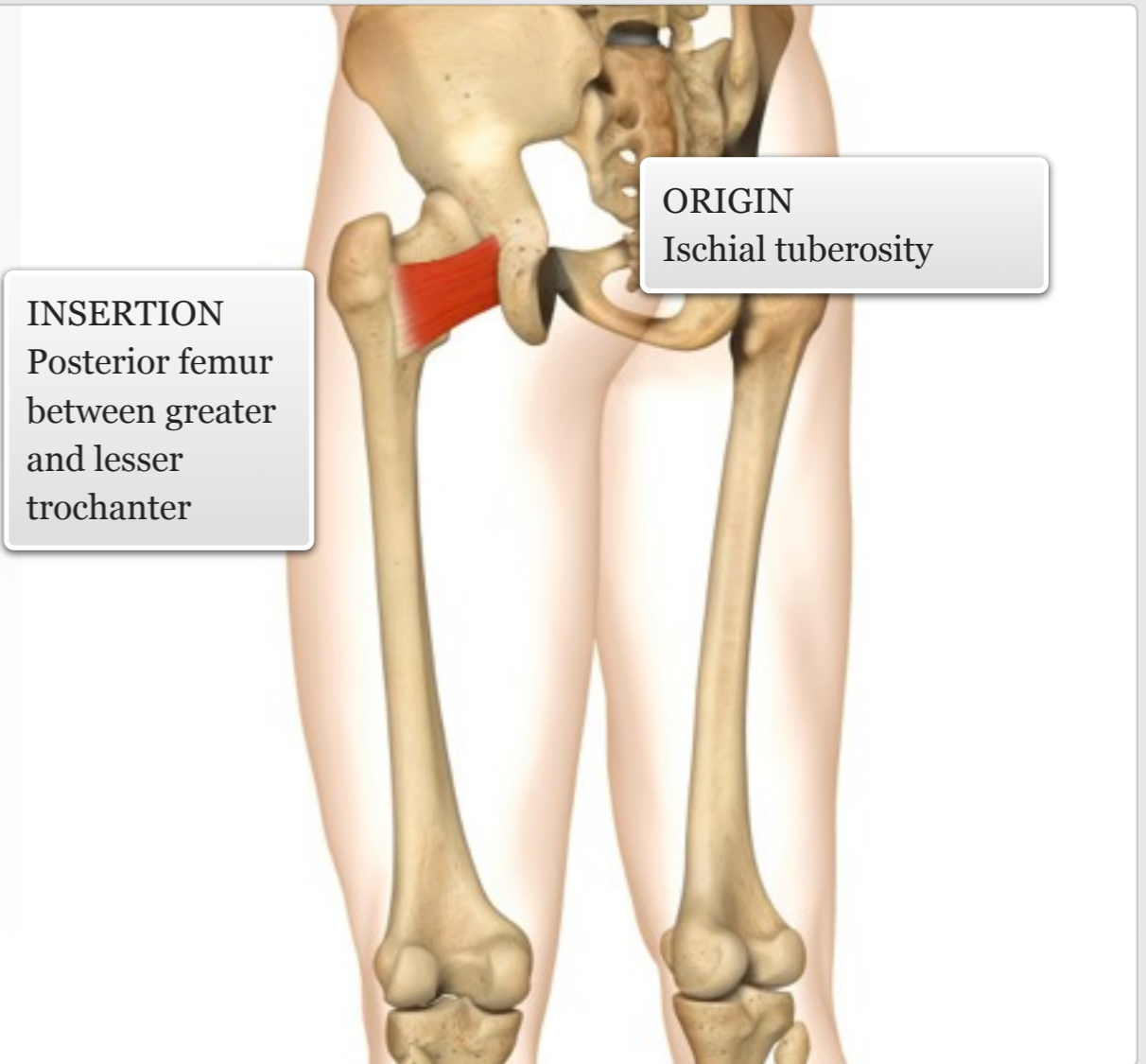
Cardio: cycling, walking/running, stepper
Resistance: stabilisation during squat, lunge, deadlift, step-up, leg press
Power: jumping, hopping
Balance: single leg balance exercises

Gym

The quadratus femoris is a flat muscle that is a strong lateral rotator of the hip; it also acts to stabilise the femoral head in the acetabulum. The muscle is aligned with the inferior gemellus above and the adductor magnus below.

MUSCLE ACTIONS: Laterally rotates the hip; assists to adduct the hip

facts



muscle

additional + knowledge



Obturator externus and internus

Audio: Obturator externus and internus



Stabilisation of pelvis during standing
Controlling rapid hip medial rotation during gait

Daily Use



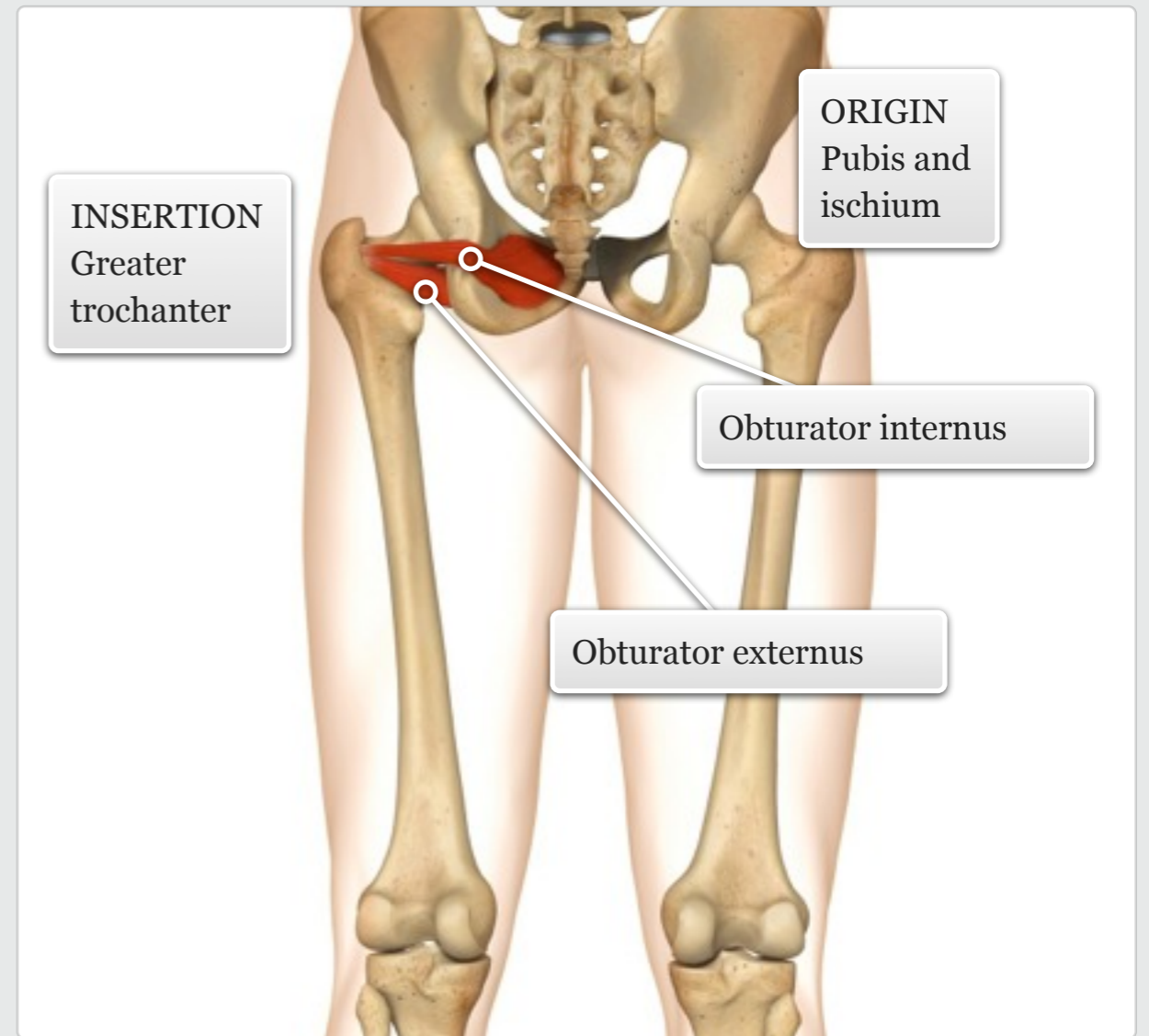
Cardio: cycling, walking/running, stepper
Resistance: stabilisation during squat, lunge, deadlift, step-up, leg press
Power: jumping, hopping
Balance: single leg balance exercises

Gym

The small obturator externus and the thicker obturator internus muscles are both fan-shaped, whose tendons cross the posterior aspect of the femoral neck. As well as laterally rotating the hip, both muscles act to stabilise the femoral head in the acetabulum.

MUSCLE ACTIONS: Laterally rotates the hip.

facts



muscle

additional + knowledge



Gemellus superior and inferior

Audio: Gemellus superior and inferior



Stabilisation of pelvis during standing

Controlling rapid hip medial rotation during gait

Daily Use



Cardio: cycling, walking/running, stepper

Resistance: stabilisation during squat, lunge, deadlift, step-up, leg press

Power: jumping, hopping

Balance: single leg balance exercises

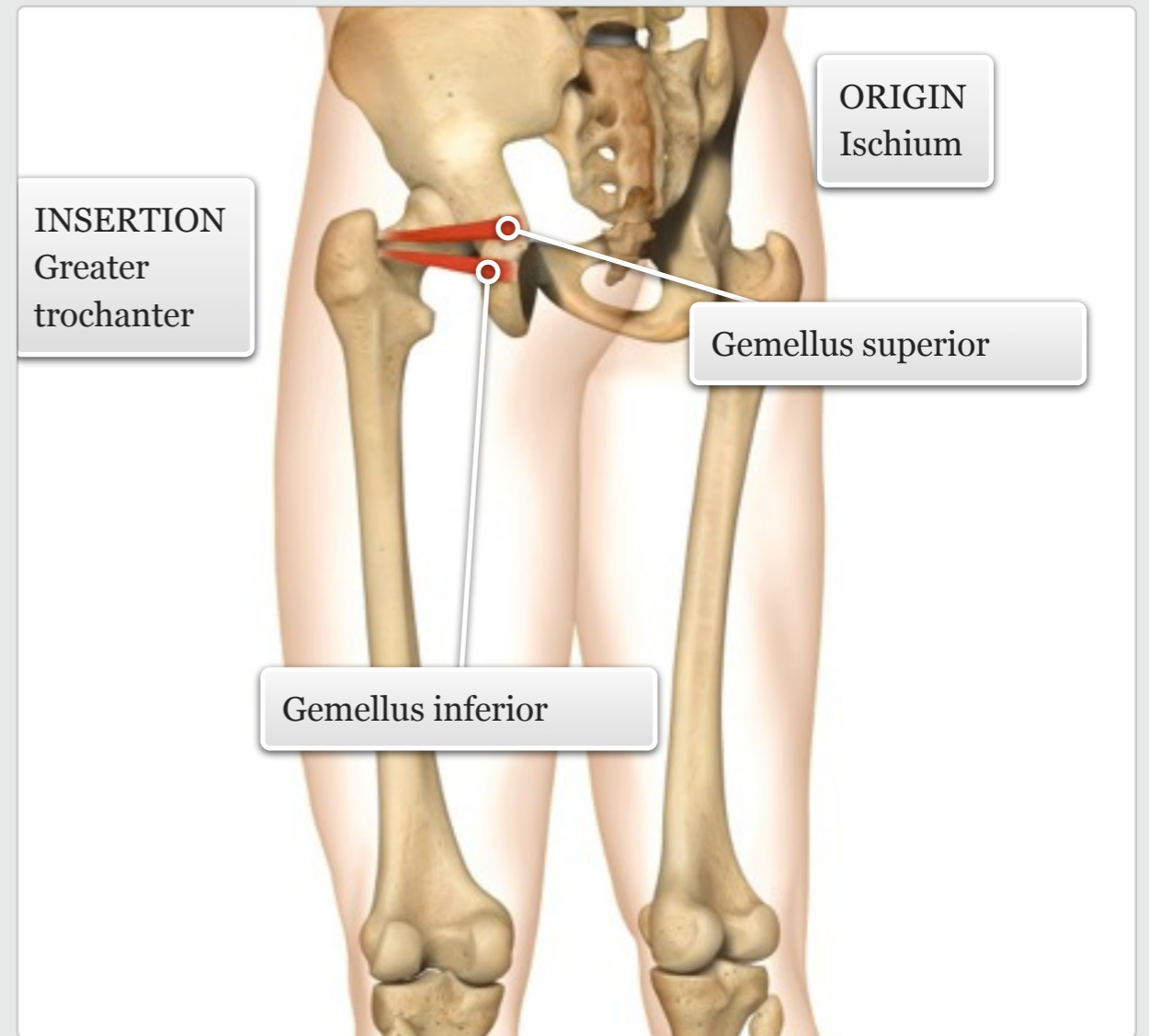
Gym

additional + knowledge

The gemellus superior and inferior are narrow, triangular muscles that are often considered as extra-pelvic parts of the obturator internus.

MUSCLE ACTIONS: Laterally rotates the hip.

facts



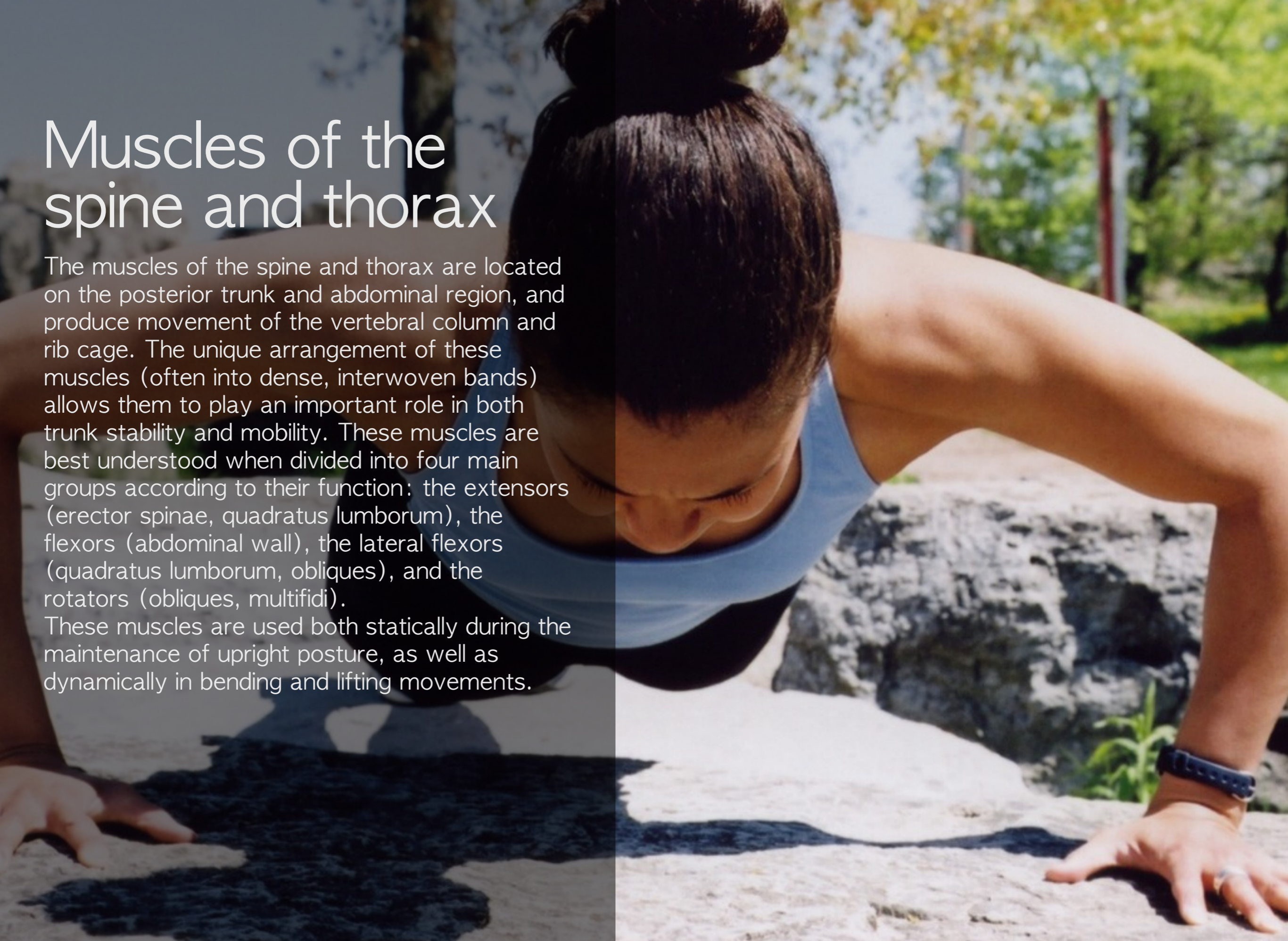muscle



Muscles of the spine and thorax

The muscles of the spine and thorax are located on the posterior trunk and abdominal region, and produce movement of the vertebral column and rib cage. The unique arrangement of these muscles (often into dense, interwoven bands) allows them to play an important role in both trunk stability and mobility. These muscles are best understood when divided into four main groups according to their function: the extensors (erector spinae, quadratus lumborum), the flexors (abdominal wall), the lateral flexors (quadratus lumborum, obliques), and the rotators (obliques, multifidi).

These muscles are used both statically during the maintenance of upright posture, as well as dynamically in bending and lifting movements.



Rectus abdominis

Audio: Rectus abdominis



Sitting up in bed
Coughing, sneezing and
defecating

Daily
Use



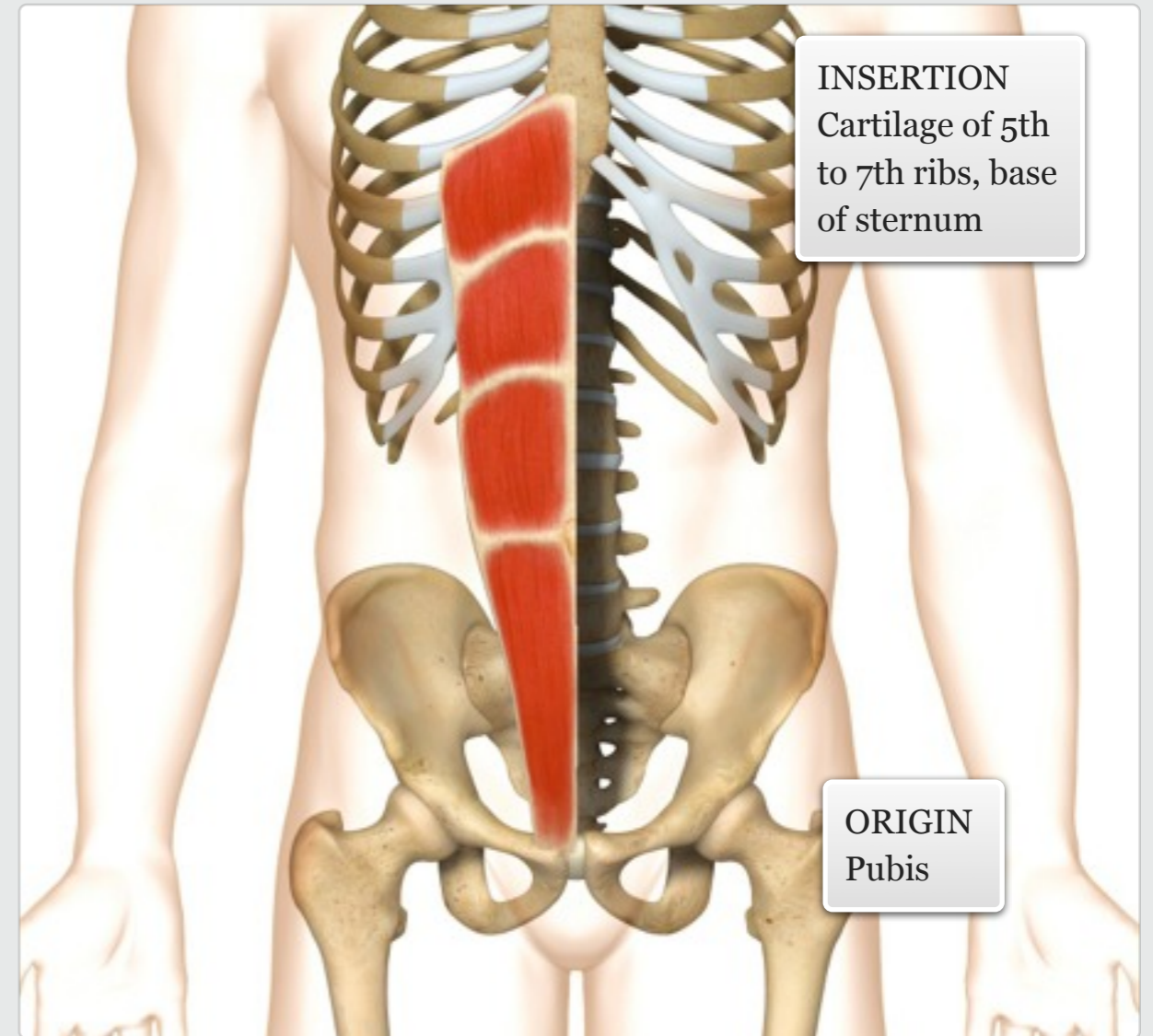
Cardio: all cardio exercises*
Resistance: specifically
crunch/sit-up variations; all
resistance exercises*
Power: all power exercises*
Balance: all balance exercises*

*any integrated exercise/movement
pattern will utilise the core musculature to
a degree, depending on load and intensity

Gym

The rectus abdominis (also known as the 'washboard' or six-pack) is a paired muscle running vertically on each side of the anterior abdominal wall, and is the most superficial of the abdominal muscles.

MUSCLE ACTIONS: Flexion and lateral flexion of the spine, posteriorly tilts the pelvis.



INSERTION
Cartilage of 5th
to 7th ribs, base
of sternum

ORIGIN
Pubis

level || knowledge

facts

muscle



Internal oblique

Audio: Internal oblique



Sitting up in bed and reaching for alarm clock
Chopping wood, raking leaves
Coughing, sneezing and defecating

Daily Use



Cardio: all cardio exercises*
Resistance: specifically torso rotation (e.g. twisting crunch); all resistance exercises*
Power: specifically throwing movements; all power exercises*
Balance: all balance exercises*

*any integrated exercise/movement pattern will utilise the core musculature to a degree, depending on load and intensity

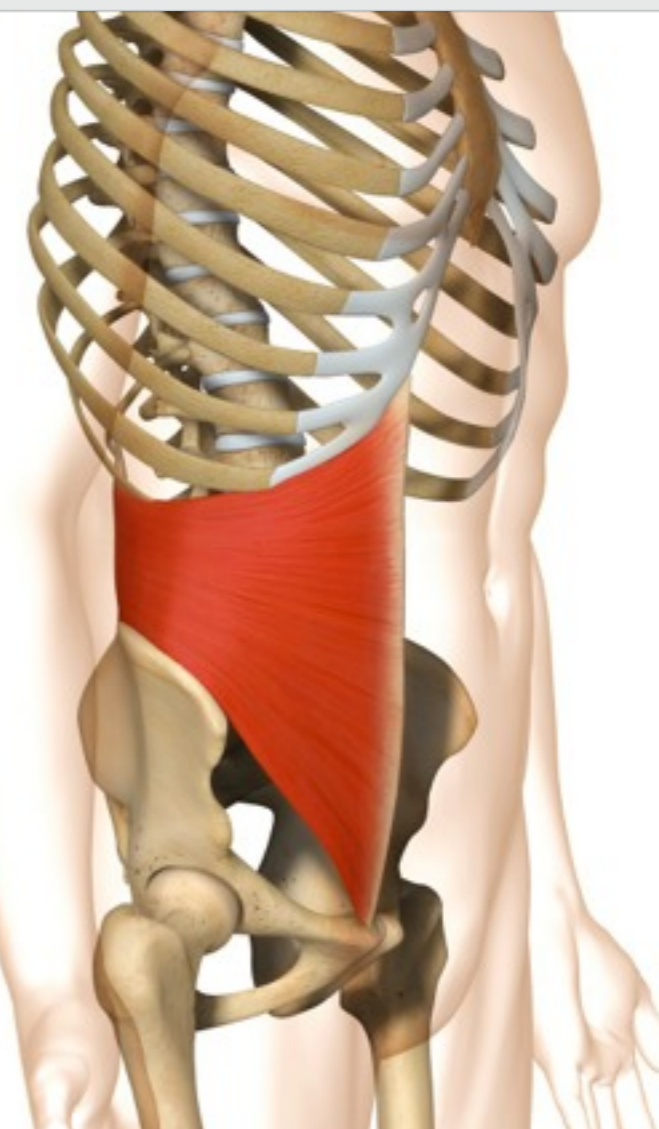
Gym

The internal oblique is a thin muscle that wraps around the waist, and whose fibres run perpendicular to the external oblique. The muscle runs up and towards the midline from its origin.

MUSCLE ACTIONS: Rotation and lateral flexion of the spine.

INSERTION
Lower 3 ribs, and the fascial connection to the linea alba

ORIGIN
Iliac crest and thoracolumbar fascia



level || knowledge

facts

muscle



External oblique

Audio: External oblique



Sitting up in bed and reaching for alarm clock
Chopping wood, raking leaves
Coughing, sneezing and defecating

Daily Use



Cardio: all cardio exercises*
Resistance: specifically torso rotation (e.g. twisting crunch); all resistance exercises*
Power: specifically throwing movements; all power exercises*
Balance: all balance exercises*

*any integrated exercise/movement pattern will utilise the core musculature to a degree, depending on load and intensity

Gym

The external oblique is the largest and the most superficial of the three flat muscles of the lateral anterior abdominal wall. It is best palpated at its attachments to the lower ribs.

MUSCLE ACTIONS: Rotation and lateral flexion of the spine.

ORIGIN
Outer surface of ribs 6-12

INSERTION
Iliac crest, pubis, and fascial connection to the linea alba

level || knowledge

facts

muscle



Quadratus lumborum

Audio: Quadratus lumborum



Hiking the hip when stepping over a box

Raising yourself up from a side lying position

Ballroom dancing (especially salsa and tango)

Daily Use



Cardio: walking, running, stepping

Resistance: side bends

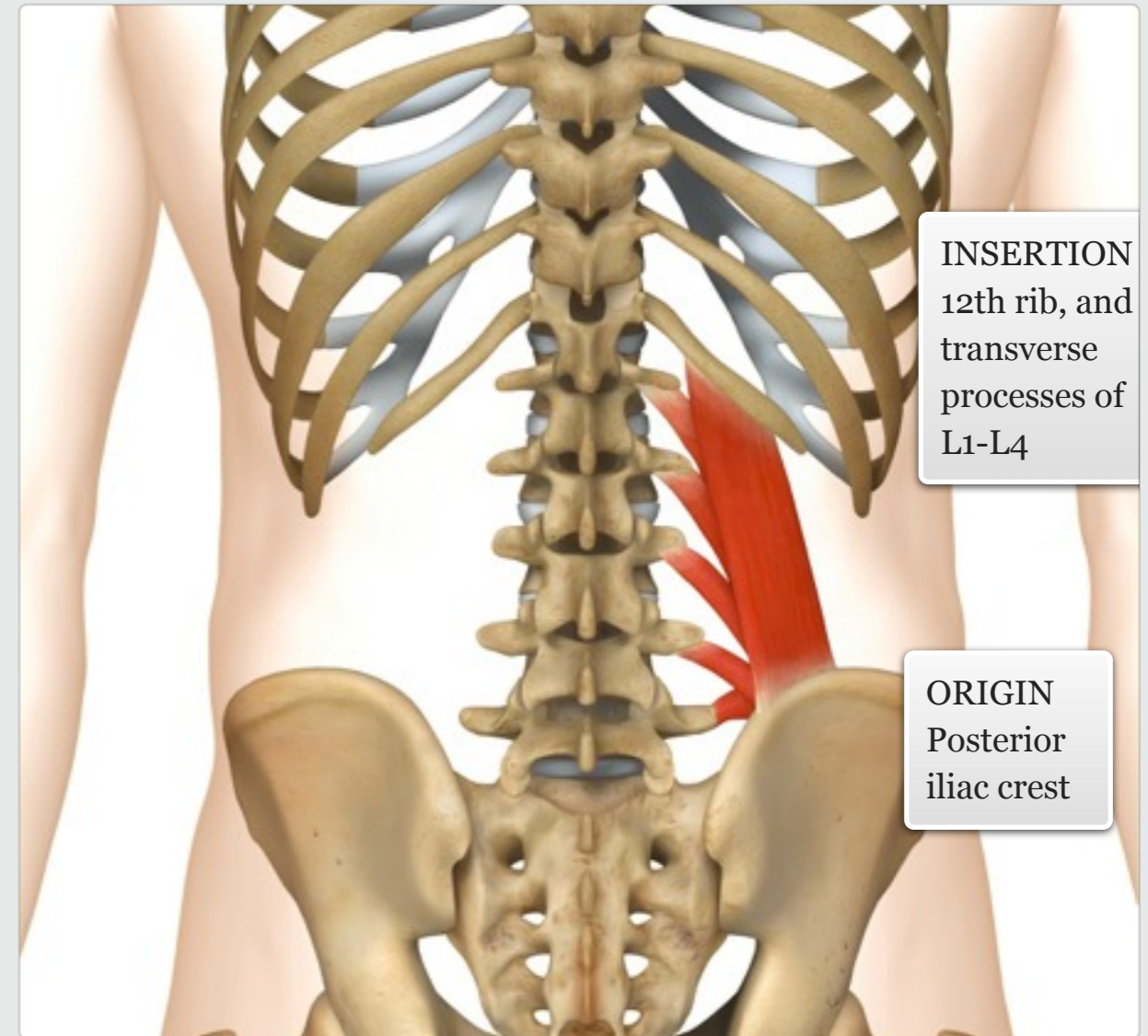
Power: hopping, kicking, jumping

Balance: single leg balance exercises (stabilisation)

Gym

The quadratus lumborum is a thick muscle, often considered to be an abdominal muscle located on the posterior surface of the thorax. Its medial portion is deep to the erector spinae, but its lateral edge is accessible from the side of the torso.

MUSCLE ACTIONS: Lateral flexion and extension of the spine, laterally tilts the pelvis.



INSERTION
12th rib, and transverse processes of L1-L4

ORIGIN
Posterior iliac crest

level || knowledge

facts

muscle



Pelvic floor muscles

Audio: Pelvic floor muscles



Coughing, sneezing
Holding the urge to defecate
or urinate

Daily
Use



Resistance: pelvic floor
contractions (Kegel
exercises)

Gym

additional + knowledge

The pelvic floor muscles is formed primarily by two levator ani and two coccygeus muscles. Along with the surrounding fascia, these sets of muscles span the inside floor of the pelvis, and help to support the abdominal/pelvic viscera.

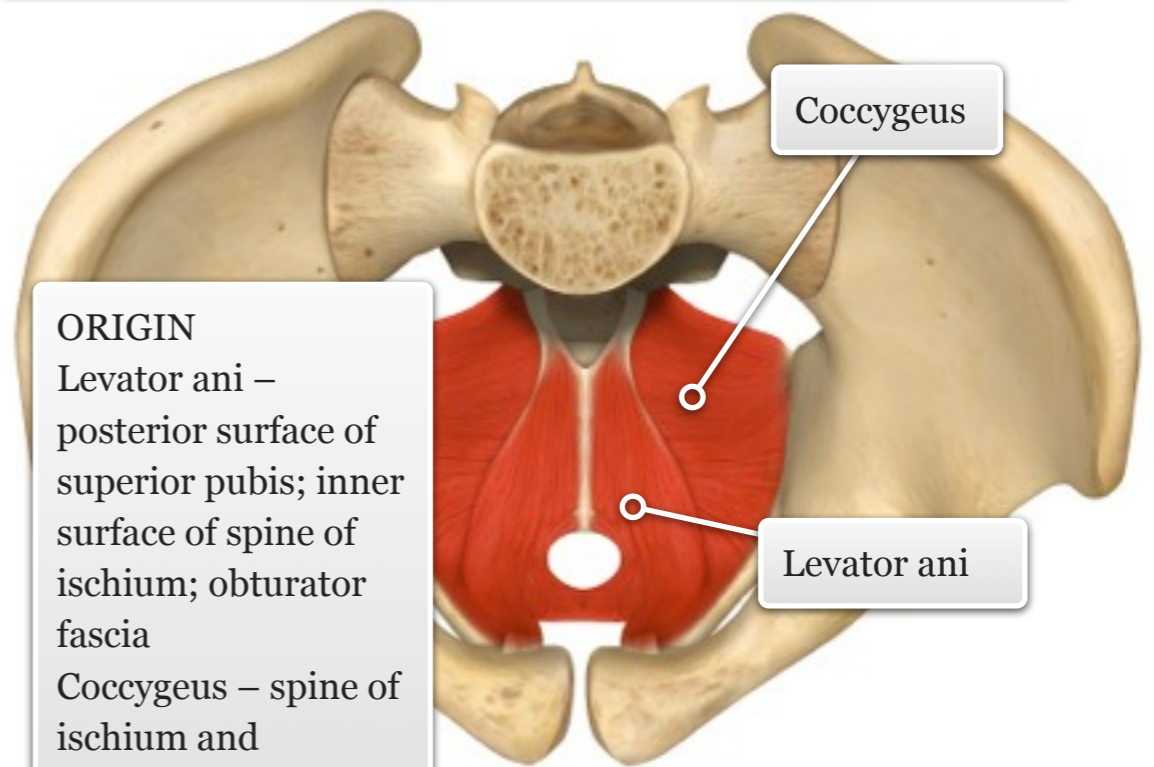
MUSCLE ACTIONS: Supports viscera; maintenance of continence; facilitates birth.

facts

INSERTION

Levator ani - coccyx, rectum, and levator ani on the other side

Coccygeus - coccyx and lower sacrum



ORIGIN

Levator ani -
posterior surface of
superior pubis; inner
surface of spine of
ischium; obturator
fascia

Coccygeus - spine of
ischium and
sacrospinous
ligament

muscle



Diaphragm

Audio: Diaphragm



Singing

Blowing up a balloon
Deep breathing during meditation

Daily Use

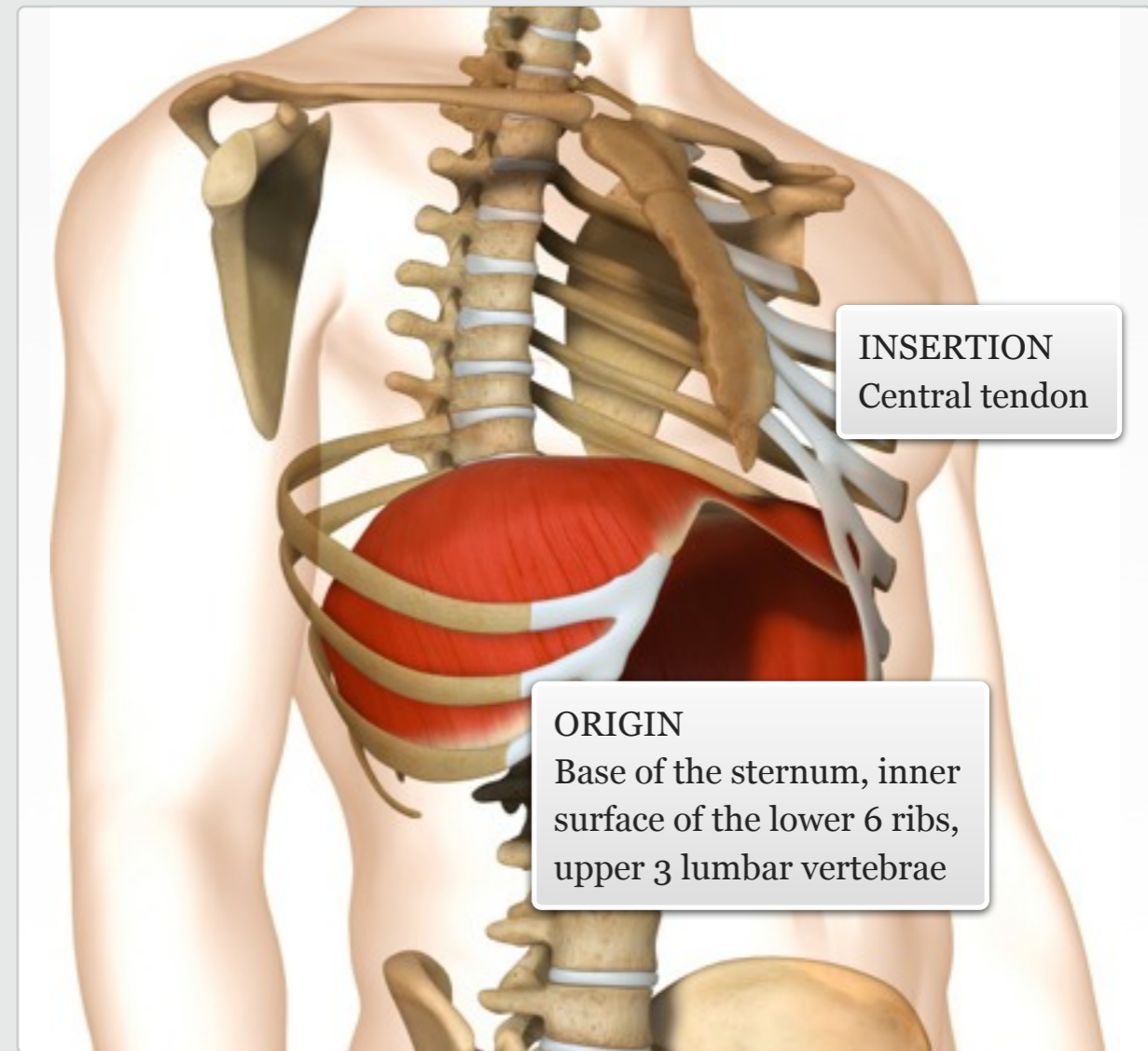


Any exercise that significantly raises heart rate or requires deeper breathing

Gym

The diaphragm is the primary muscle of respiration. Its broad dome-like shape separates the upper and lower thoracic cavities, and its fibres have a number of attachments that converge at a central tendon.

MUSCLE ACTIONS: Draws down central tendon of diaphragm; increases volume of thorax during inhalation.



INSERTION
Central tendon

ORIGIN
Base of the sternum, inner surface of the lower 6 ribs, upper 3 lumbar vertebrae

level || knowledge

facts

muscle



Intercostal muscles

Audio: Intercostal muscles



Singing

Blowing up a balloon
Deep breathing during meditation

Daily Use

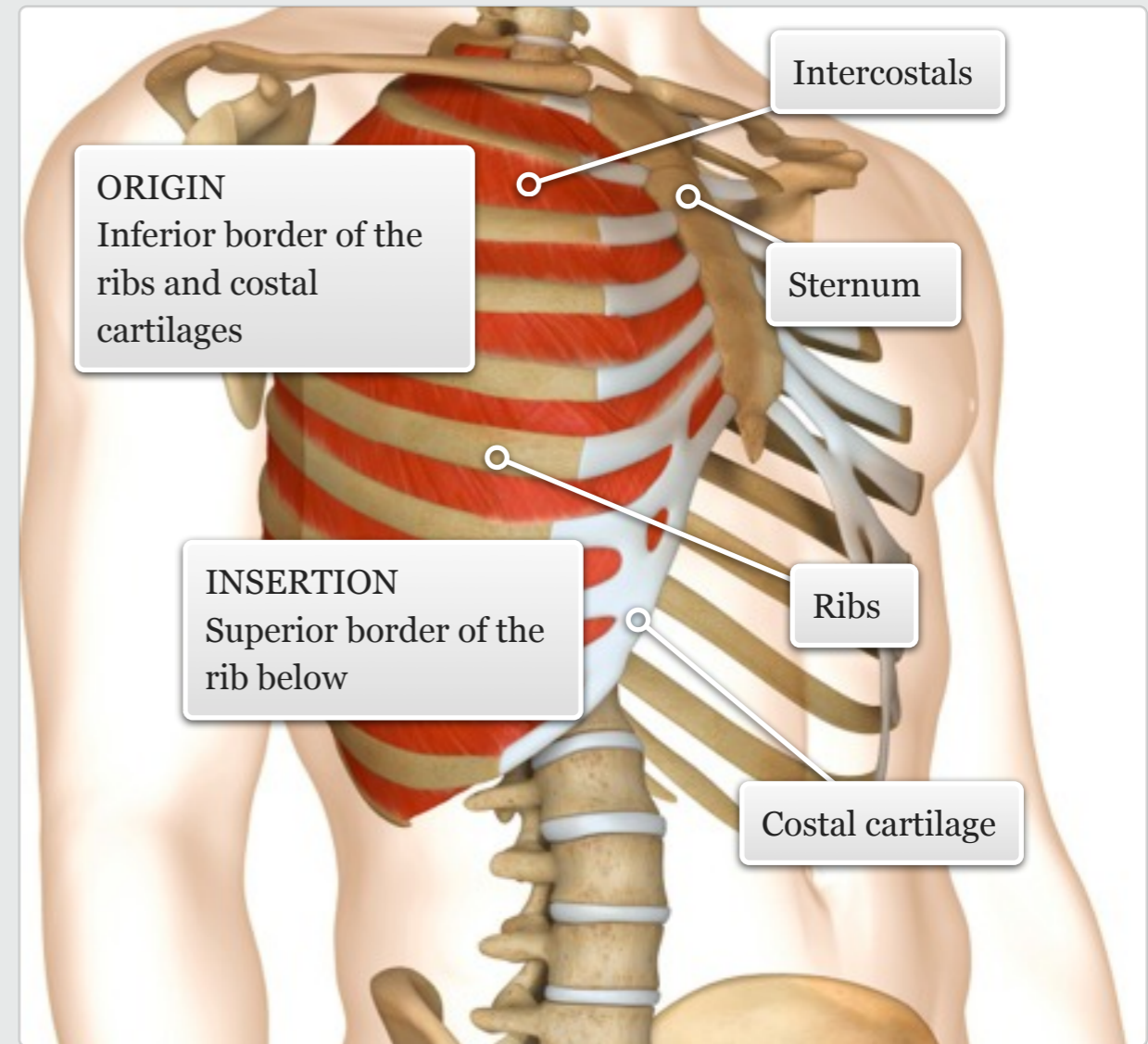


Any exercise that significantly raises heart rate or requires deeper breathing

Gym

The intercostal muscles are small slender muscles between the ribs, and are well known as the meat on 'spare ribs'. The fibres of these two muscle groups run perpendicular to each other. They help to stabilise the rib cage and assist in respiration.

MUSCLE ACTIONS: Elevate ribs to aid inspiration, draw ribs down to aid expiration.



level || knowledge

facts

muscle



Thoracolumbar fascia and muscles

Audio: Thoracolumbar fascia and muscles



N/A

Daily Use

The thoracolumbar fascia is a large diamond-shaped sheet that is most developed in the lumbar region. A number of back muscles lie within the criss-cross layers of the fascia, and the fascia is also continuous with a number of muscles, including the gluteus maximus, transversus abdominis, latissimus dorsi, and trapezius.

The fascia has three layers - anterior, middle, and posterior.

The muscles that connect into the three layers of the thoracolumbar fascia help to provide both a stabilizing and biomechanical role for the body.



N/A

Gym

additional + knowledge

facts

Thoracolumbar fascia

Trapezius

Latissimus dorsi

Gluteus maximus

Transversus abdominis

muscle



Erector spinae group

Audio: Erector spinae group



Maintaining upright posture
Bending to the side to pick up
a bag or suitcase
Returning to standing after
tying your shoelaces

Daily
Use



N/A

Gym

level || knowledge

Spinalis

Longissimus

Iliocostalis

The erector spinae group runs from the sacrum to the base of the skull. The group has three main branches – spinalis, longissimus, and iliocostalis.

The spinalis is the smallest of the erector spinae muscles, and lies closest to the spine in the lamina groove. The thick longissimus and iliocostalis form a visible mound alongside the lumbar and thoracic spine.

MUSCLE ACTIONS: Extension and lateral flexion of the spine.

facts

INSERTION
Ribs, vertebrae, and
base of skull

C-7

T-12

L-5

ORIGIN
Sacrum, ilium, ribs and vertebrae

Spinalis

Longissimus

Iliocostalis

Thoracolumbar
aponeurosis

muscle



Spinalis

Audio: Spinalis



Maintaining upright posture
Bending to the side to pick up
a bag or suitcase

Returning to standing after
tying your shoelaces

Daily
Use



Cardio: any exercise or
movement that requires the
spine to be held unsupported,
e.g. running, cycling, rowing

Resistance: any exercise or
movement that requires the
spine to be held unsupported
and/or extend within a
functional range of motion,
e.g. squatting, lunging,
stability ball back extension

Gym

MUSCLE ACTIONS: Lateral flexion and
extension of the spine

GYM USE CONTINUED:

Power: any exercise or movement that
requires the spine to stabilise or extend/
rotate explosively, e.g. jumping,
backward/oblique ball toss

Balance: any exercise or movement
that requires the spine to be held
unsupported, e.g. single leg balance

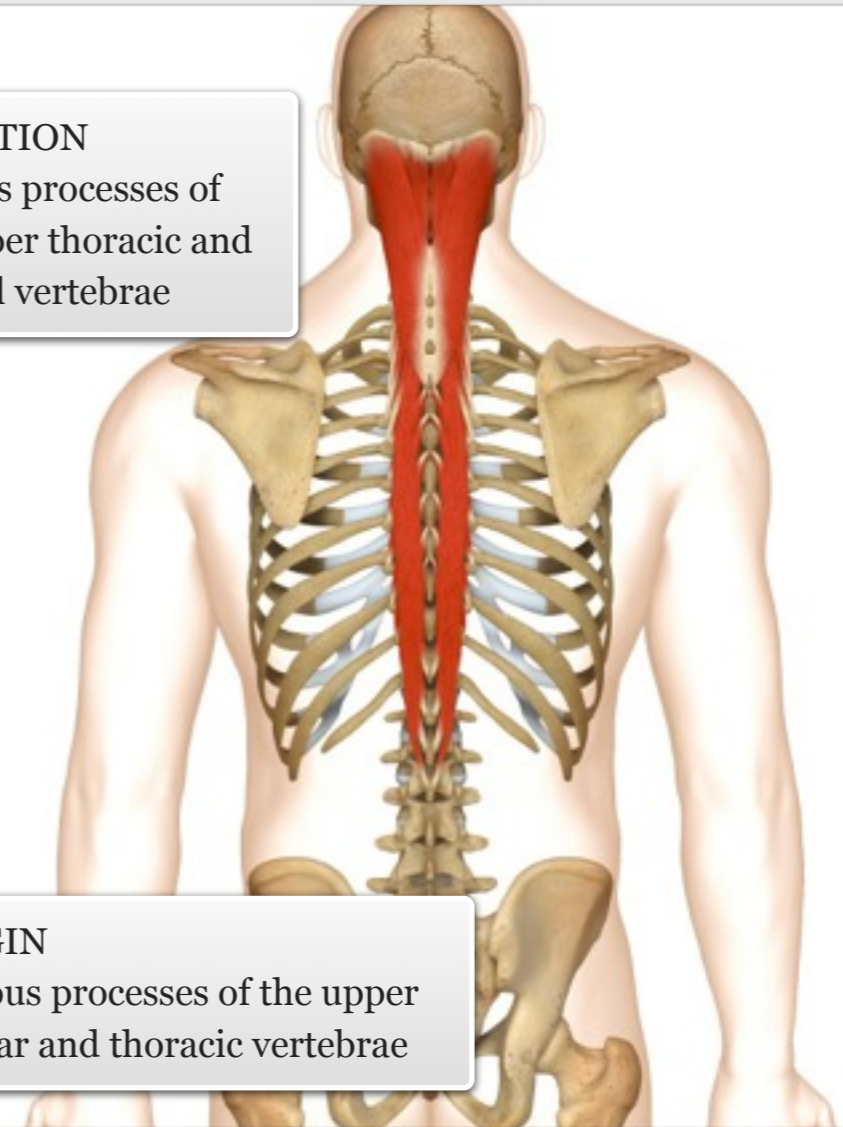
facts

INSERTION

Spinous processes of
the upper thoracic and
cervical vertebrae

ORIGIN

Spinous processes of the upper
lumbar and thoracic vertebrae



muscle

level ||| knowledge



Longissimus

Audio: Longissimus



Maintaining upright posture
Bending to the side to pick up
a bag or suitcase

Returning to standing after
tying your shoelaces

Daily
Use



Cardio: any exercise or
movement that requires the
spine to be held unsupported,
e.g. running, cycling, rowing

Resistance: any exercise or
movement that requires the
spine to be held unsupported
and/or extend within a
functional range of motion,
e.g. squatting, lunging,
stability ball back extension

Gym

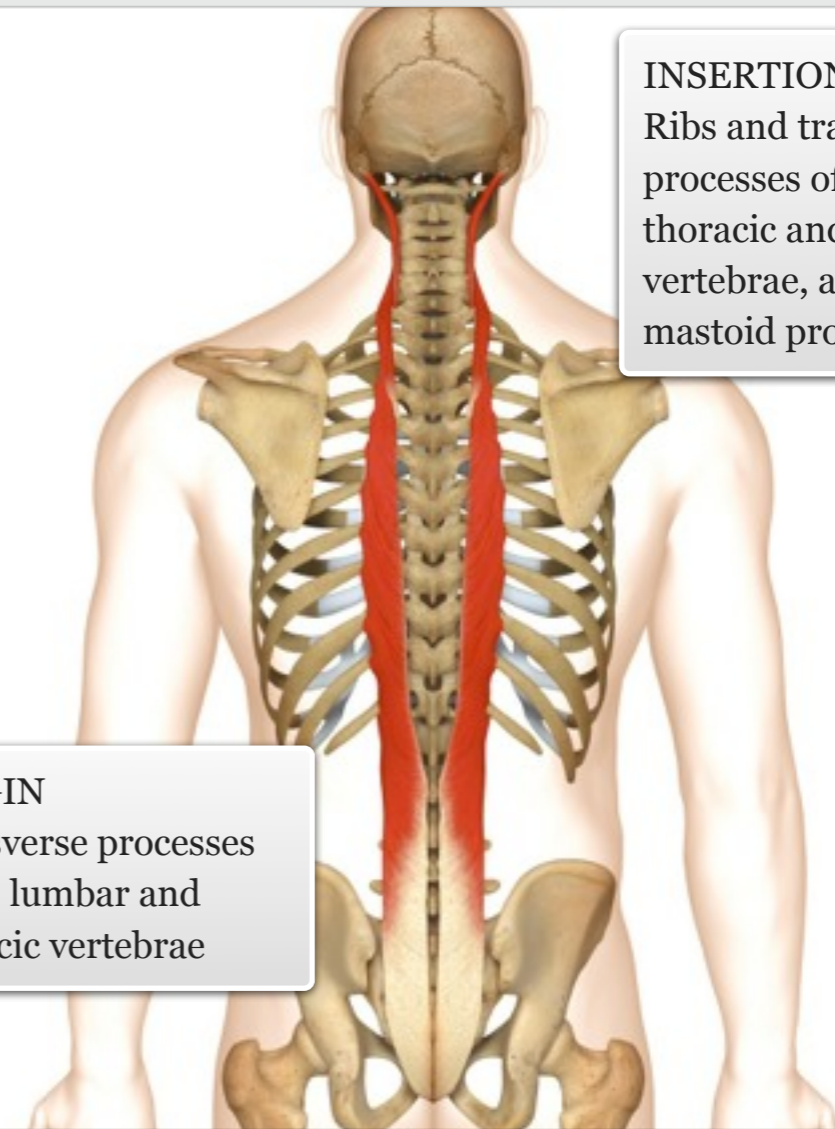
MUSCLE ACTIONS: Lateral flexion and
extension of the spine

GYM USE CONTINUED:

Power: any exercise or movement that
requires the spine to stabilise or extend/
rotate explosively, e.g. jumping,
backward/oblique ball toss

Balance: any exercise or movement
that requires the spine to be held
unsupported, e.g. single leg balance

facts



INSERTION
Ribs and transverse
processes of the
thoracic and cervical
vertebrae, and
mastoid process

ORIGIN
Transverse processes
of the lumbar and
thoracic vertebrae

level ||| knowledge

muscle



Iliocostalis

Audio: Iliocostalis



Maintaining upright posture
Bending to the side to pick up
a bag or suitcase

Returning to standing after
tying your shoelaces

Daily
Use



Cardio: any exercise or
movement that requires the
spine to be held unsupported,
e.g. running, cycling, rowing

Resistance: any exercise or
movement that requires the
spine to be held unsupported
and/or extend within a
functional range of motion,
e.g. squatting, lunging,
stability ball back extension

Gym

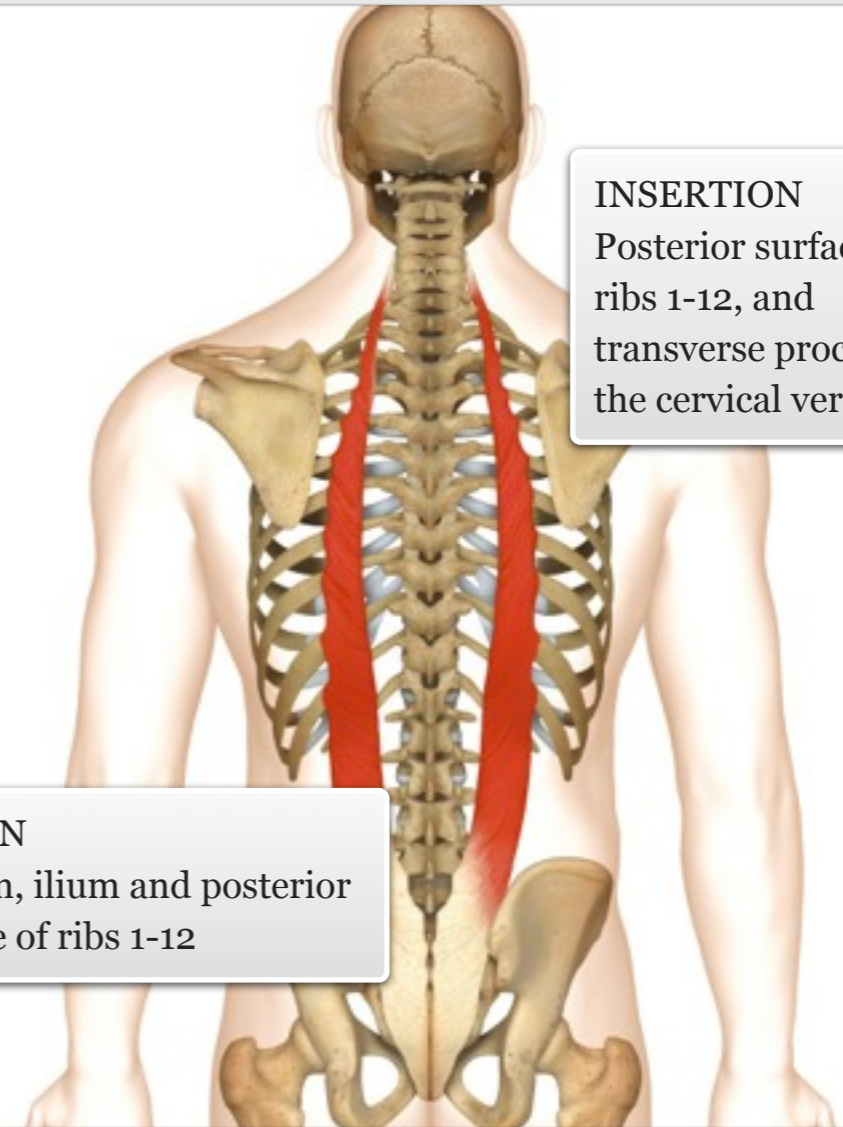
MUSCLE ACTIONS: Lateral flexion and
extension of the spine

GYM USE CONTINUED:

Power: any exercise or movement that
requires the spine to stabilise or extend/
rotate explosively, e.g. jumping,
backward/oblique ball toss

Balance: any exercise or movement
that requires the spine to be held
unsupported, e.g. single leg balance

facts



INSERTION
Posterior surface of
ribs 1-12, and
transverse processes of
the cervical vertebrae

ORIGIN
Sacrum, ilium and posterior
surface of ribs 1-12

level ||| knowledge

muscle



Multifidus

Audio: Multifidus



Turning to put on a seatbelt
Stretching/rotating during a yawn
Returning from any bending movement

Daily Use



Any exercise that requires the control and maintenance of optimal posture, particularly during spinal extension and rotation

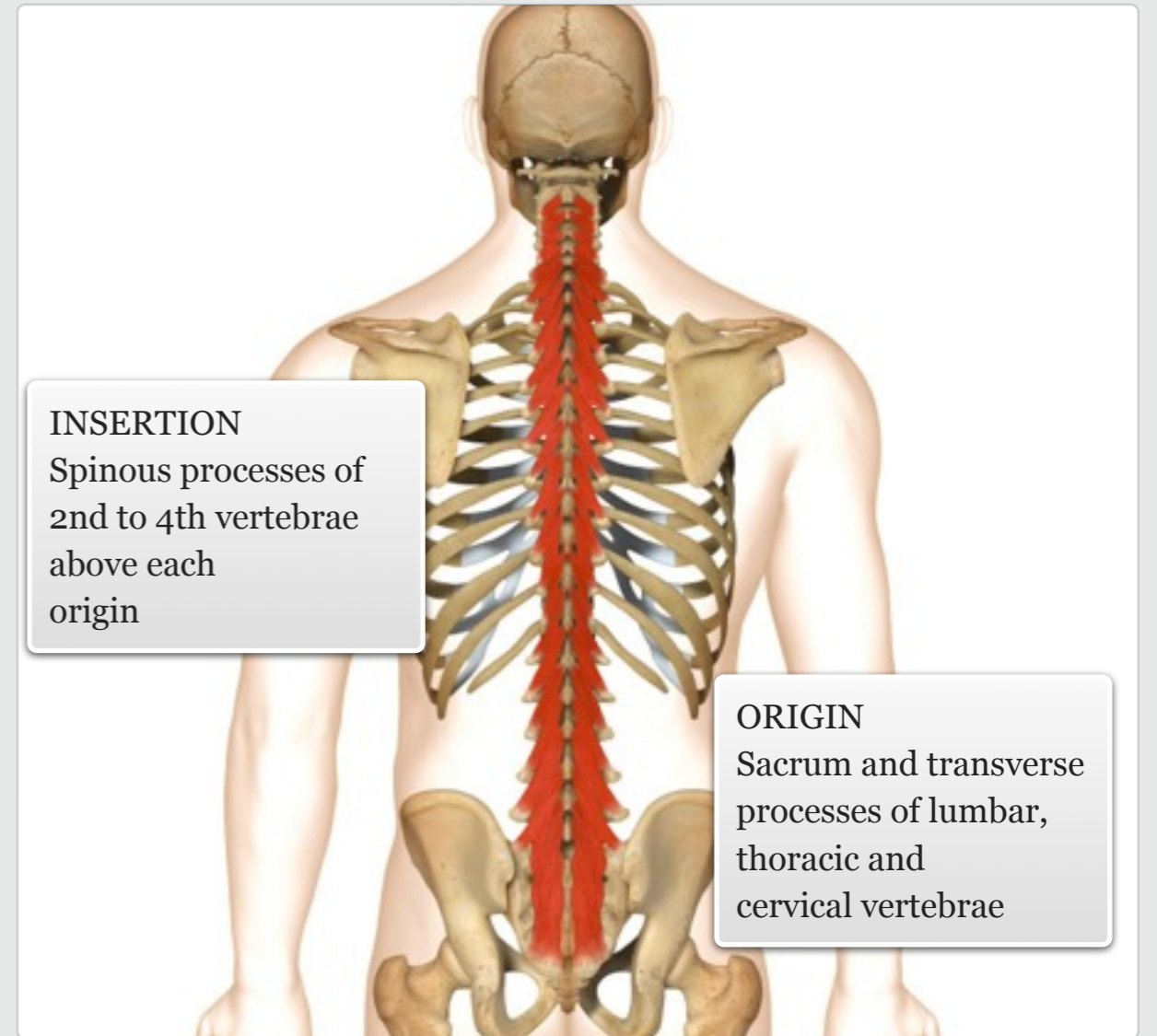
Gym

level ||| knowledge

The multifidus is a series of small muscles which travel up the length of the spine. These surprisingly thick muscles are accessible in the lumbar region, and are the only muscles that have fibres lying across the posterior surface of the sacrum.

MUSCLE ACTIONS: Extension and rotation of the spine

facts



muscle



Rotatores, interspinalis and intertransversarii

Audio: Rotatores, interspinalis and intertransversarii



Sitting, standing and moving with an unsupported spine

Daily Use



Any exercise that requires the control and maintenance of optimal posture, particularly during spinal extension, rotation and lateral flexion

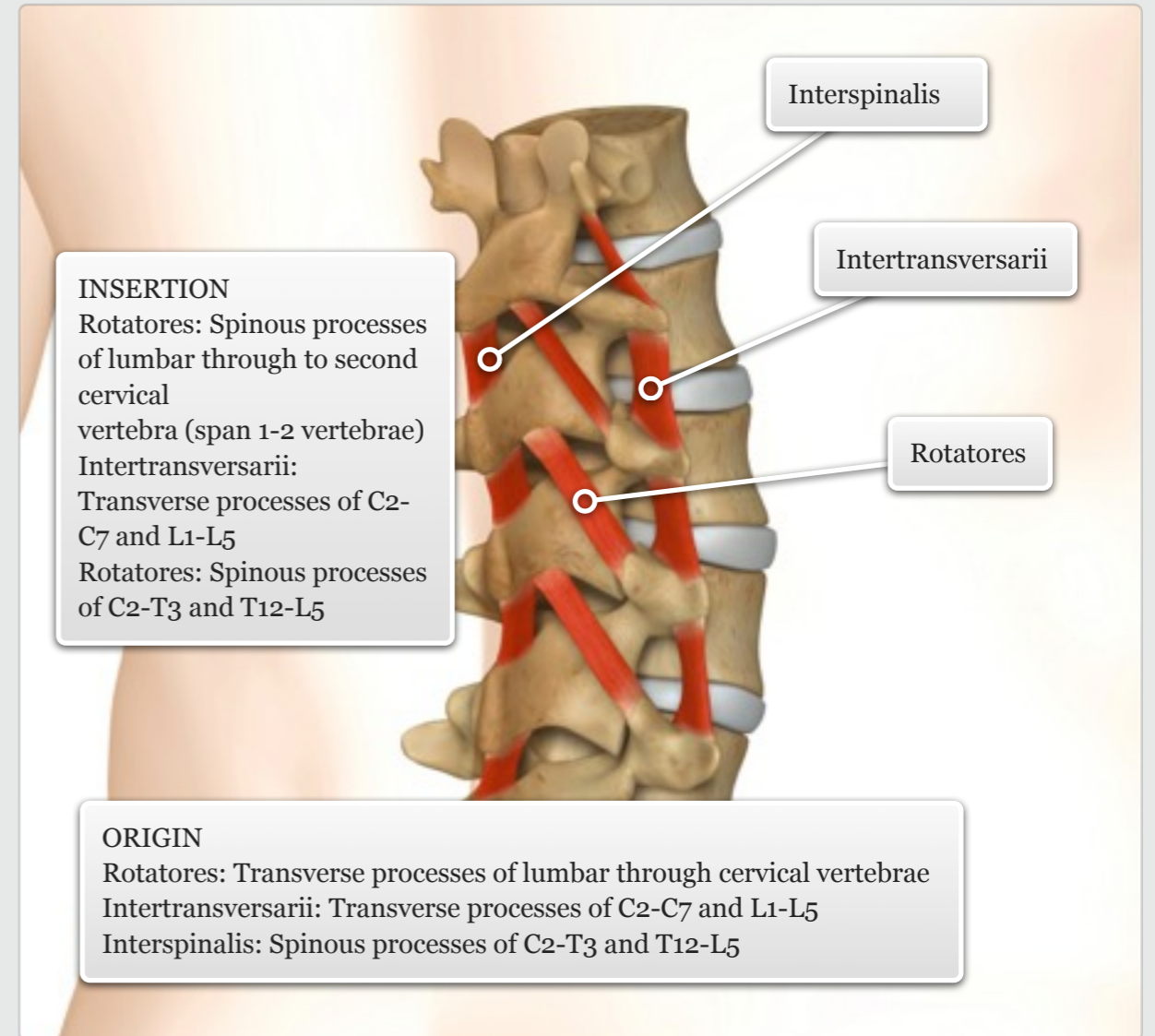
Gym

additional + knowledge

The rotatores lie deep to the multifidi and span the entire spine; the intertransversarii are the deepest muscles in the cervical and lumbar regions, spanning between the transverse processes. The interspinalis muscles span the cervical and lumbar regions between the spinous processes of adjacent vertebrae.

MUSCLE ACTIONS: Rotatores: Extension of the spine (all muscles); rotation of the spine to opposite side (rotatores); lateral flexion of the spine to same side (intertransversarii)

facts



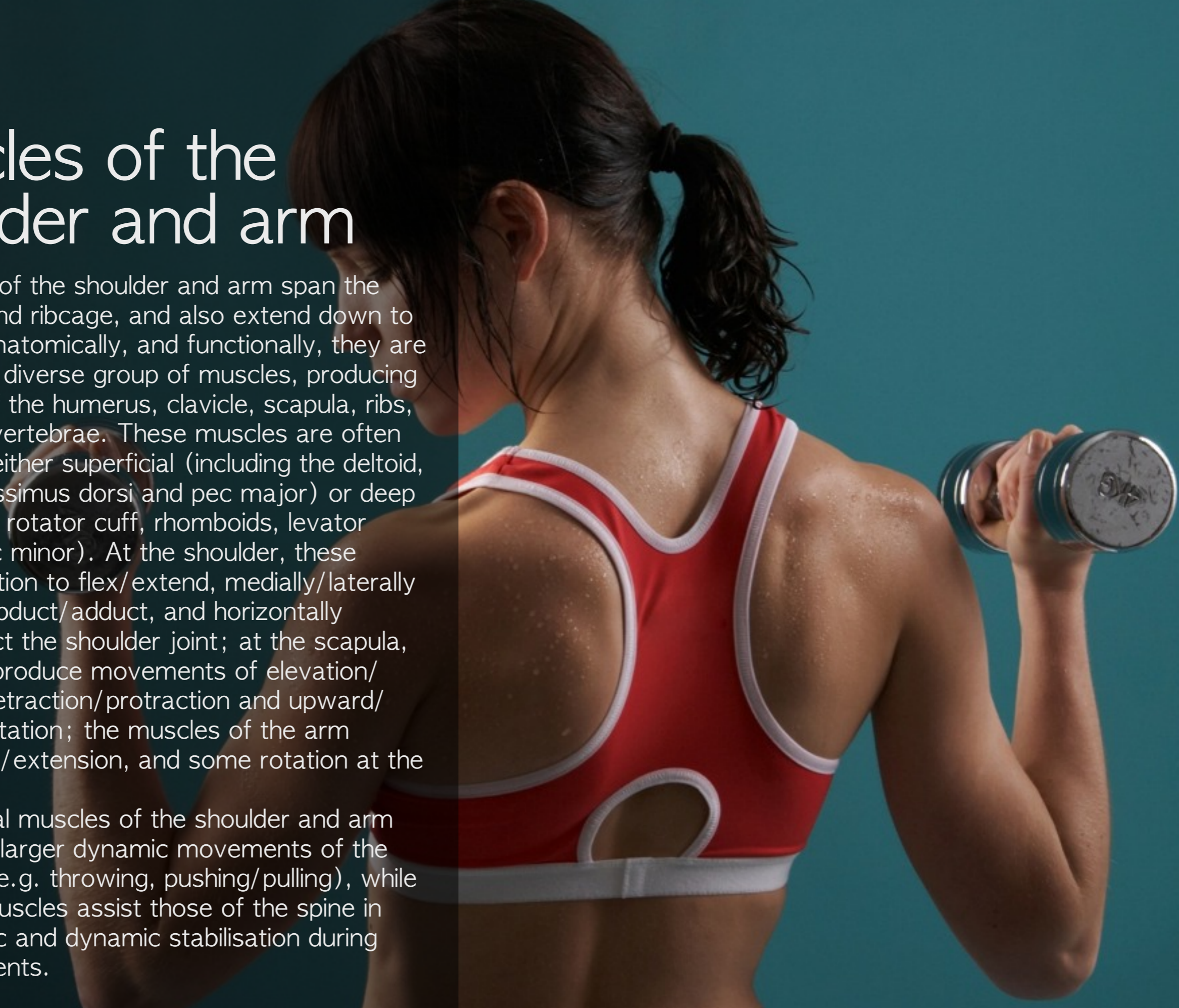muscle



Muscles of the shoulder and arm

The muscles of the shoulder and arm span the entire back and ribcage, and also extend down to the elbow. Anatomically, and functionally, they are an extremely diverse group of muscles, producing movement of the humerus, clavicle, scapula, ribs, and cervical vertebrae. These muscles are often classified as either superficial (including the deltoid, trapezus, latissimus dorsi and pec major) or deep (including the rotator cuff, rhomboids, levator scapulae, pec minor). At the shoulder, these muscles function to flex/extend, medially/laterally rotate, and abduct/adduct, and horizontally abduct/adduct the shoulder joint; at the scapula, the muscles produce movements of elevation/depression, retraction/protraction and upward/downward rotation; the muscles of the arm create flexion/extension, and some rotation at the elbow joint.

The superficial muscles of the shoulder and arm contribute to larger dynamic movements of the upper body (e.g. throwing, pushing/pulling), while the deeper muscles assist those of the spine in creating static and dynamic stabilisation during such movements.



Rhomboid group

Audio: Rhomboid group



Sticking out the chest
Shrugging the shoulders
Stretching the chest upon waking
Pulling open a drawer

Daily Use



N/A

Gym

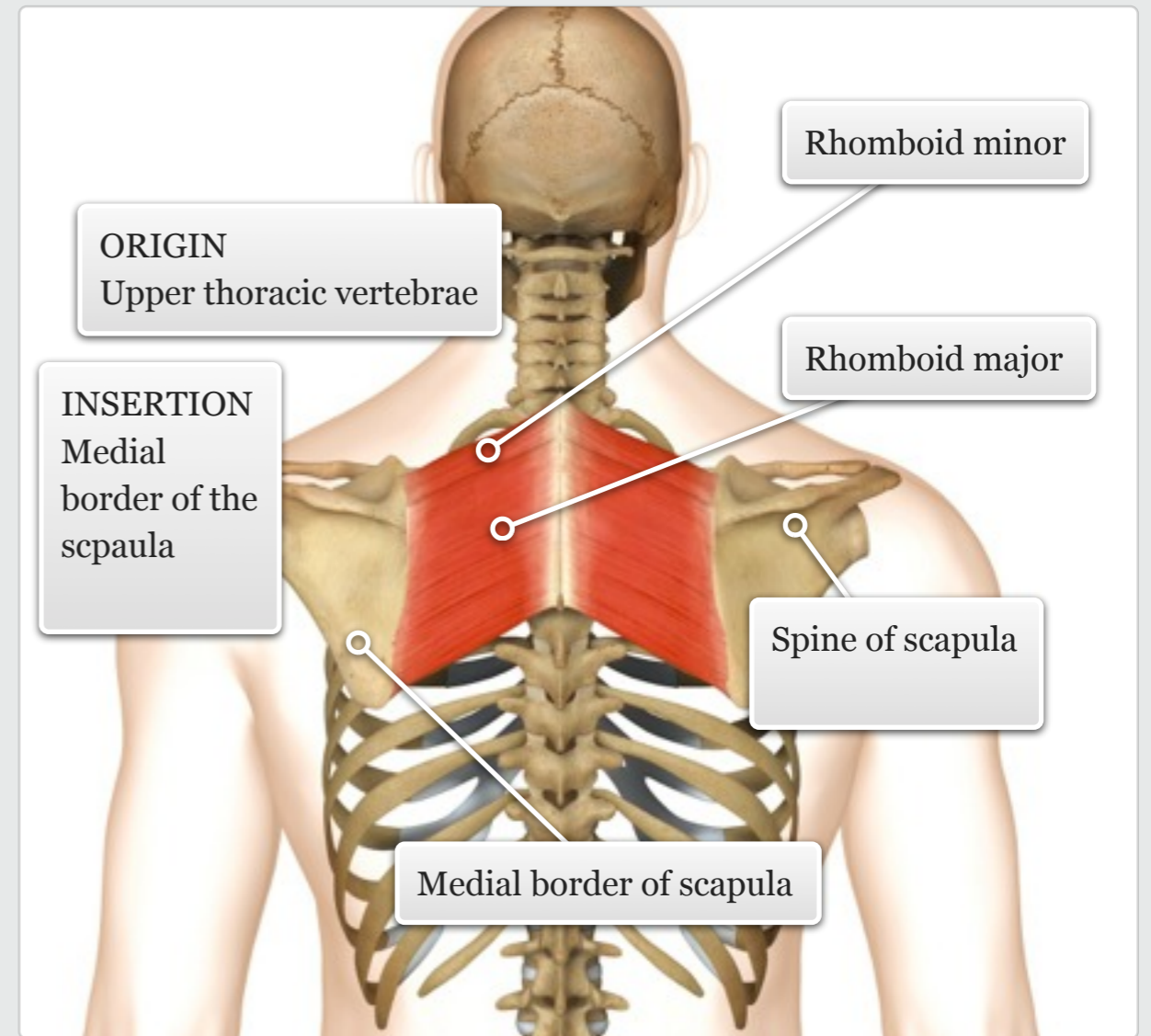
Rhomboid major

Rhomboid minor

The rhomboids are located between the scapula and spine, and are so-called, because of their geometric shape. The rhomboid major is larger than the minor, although they are difficult to distinguish individually. These muscles lie deep to the trapezius, and superficial to the erector spinae.

MUSCLE ACTIONS: Retraction and elevation of the scapula

facts



muscle

level || knowledge

Rhomboid major

Audio: Rhomboid major



Sticking out the chest
Shrugging the shoulders
Stretching the chest upon waking
Pulling open a drawer

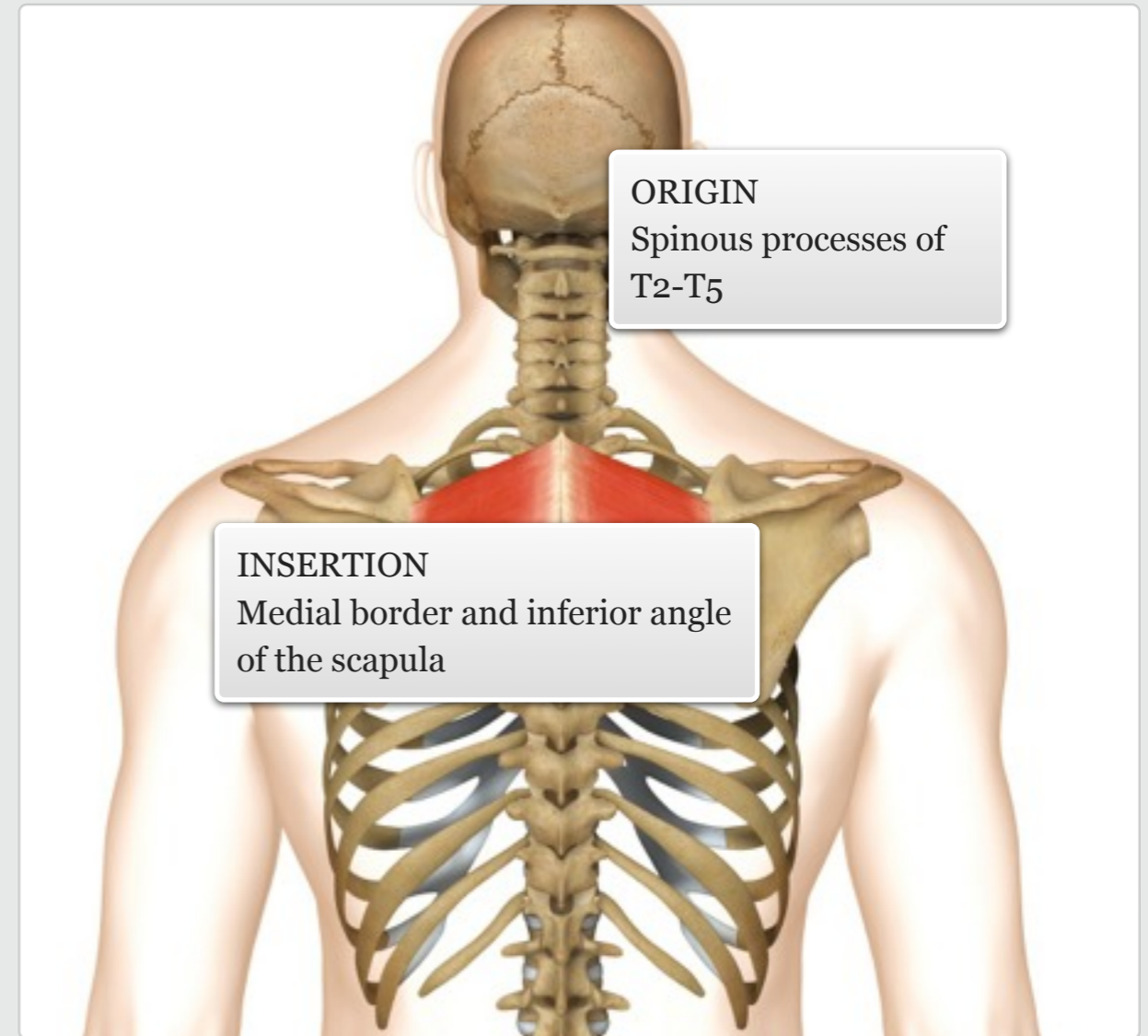
Daily Use



Cardio: rowing, cross trainer, Nordic skiing, swimming
Resistance: any type of rowing exercise (e.g. seated, bent over etc.); reverse flyes
Power: all types of throwing actions, swinging a bat/racket
Balance: upper body balance exercises, e.g. push up, single arm-leg reach, side bridge/support

Gym

MUSCLE ACTIONS: Retraction and elevation of the scapula



level ||| knowledge

facts

muscle



Rhomboid minor

Audio: Rhomboid minor



Sticking out the chest
Shrugging the shoulders
Stretching the chest upon waking
Pulling open a drawer

Daily
Use

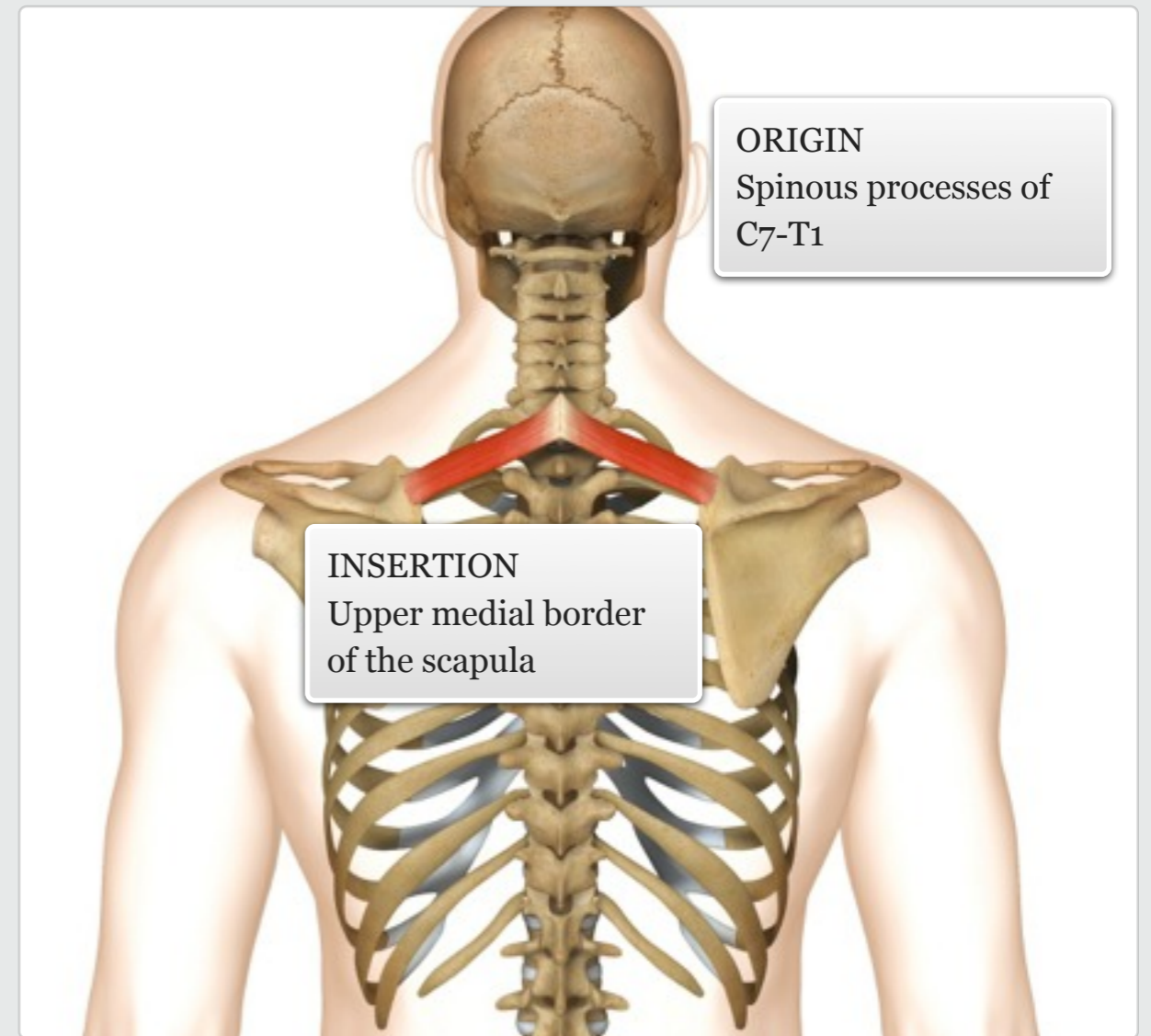


Cardio: rowing, cross trainer, Nordic skiing, swimming
Resistance: any type of rowing exercise (e.g. seated, bent over etc.); reverse flyes
Power: all types of throwing actions, swinging a bat/racket
Balance: upper body balance exercises, e.g. push up, single arm-leg reach, side bridge/support

Gym

MUSCLE ACTIONS: Retraction and elevation of the scapula

facts



muscle

level ||| knowledge



Trapezius

Audio: Trapezius



Shrugging the shoulders
Holding a phone between ear
and shoulder
Carrying a rucksack

Daily
Use

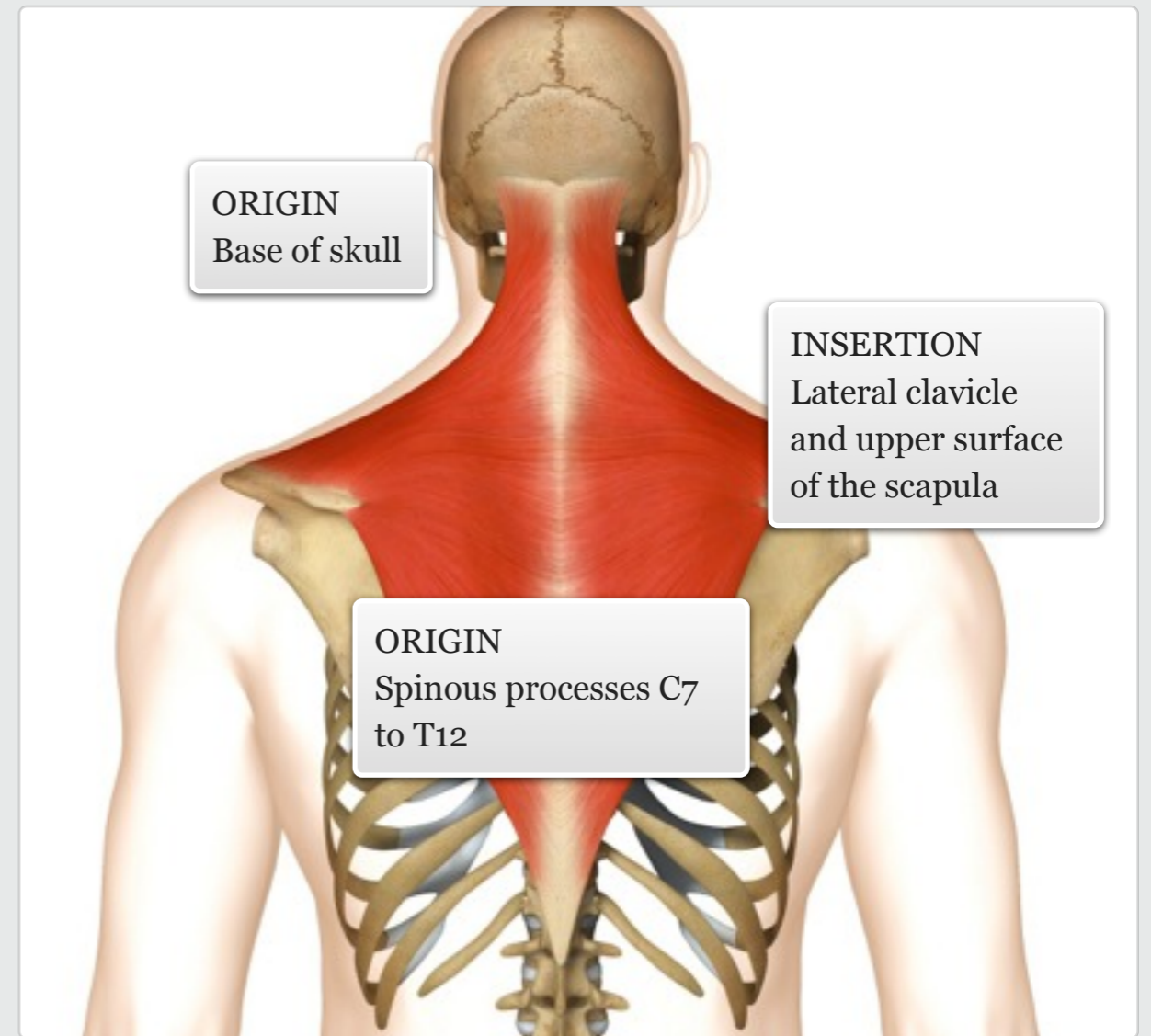


Cardio: rowing, swimming,
cycling (when out of seat)
Resistance: barbell/dumbbell
shrugs, upright rows
Power: 'clean' portion of
clean and jerk
Balance: handstand

Gym

The trapezius lies superficially across the neck and upper/middle back, appearing like a 'cape' over the shoulders. Its fibres can be divided into three groups – upper, middle and lower – and all fibres are easy to palpate.

MUSCLE ACTIONS: Elevation, retraction, and depression of shoulder girdle; extension, lateral flexion and rotation of the neck



level || knowledge

facts

muscle



Levator scapulae

Audio: Levator scapulae



Looking over the shoulder
Carrying a heavy shopping bag
Side-lying in bed on a pillow

Daily
Use



Cardio: rowing, swimming,
cycling (when out of seat)
Resistance: barbell/dumbbell
shrugs
Power: 'clean' portion of
clean and jerk

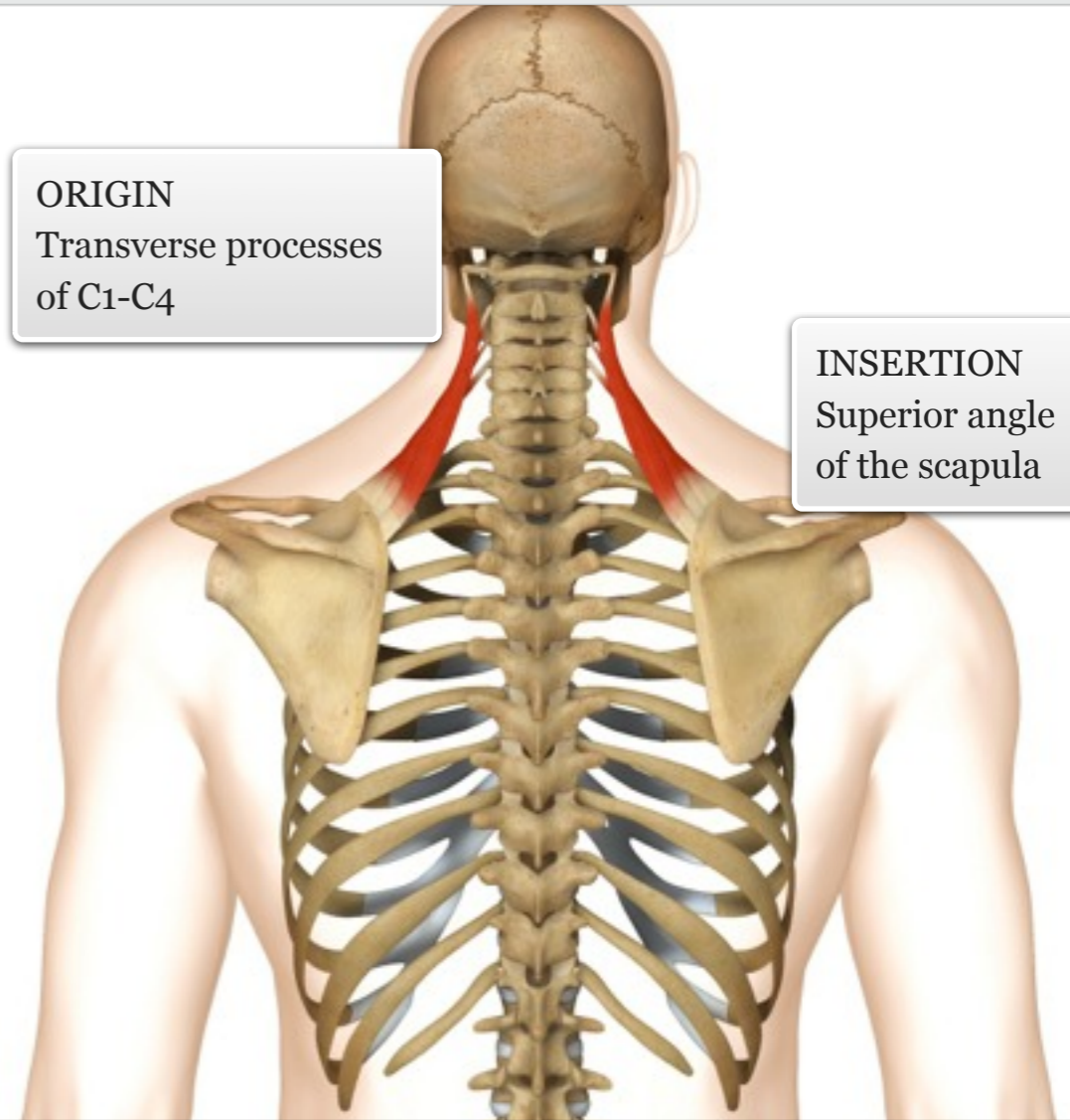
Gym

The levator scapulae is positioned along the lateral and posterior side of the neck, and is easy to palpate through the fibres of the upper trapezius, as well as from the side of the neck.

MUSCLE ACTIONS: Elevation of the shoulder girdle, lateral flexion and extension of the neck

ORIGIN
Transverse processes
of C1-C4

INSERTION
Superior angle
of the scapula



level || knowledge

facts

muscle



Latissimus dorsi

Audio: Latissimus dorsi



Walking with crutches
Rope climbing
Paddling a canoe

Daily
Use

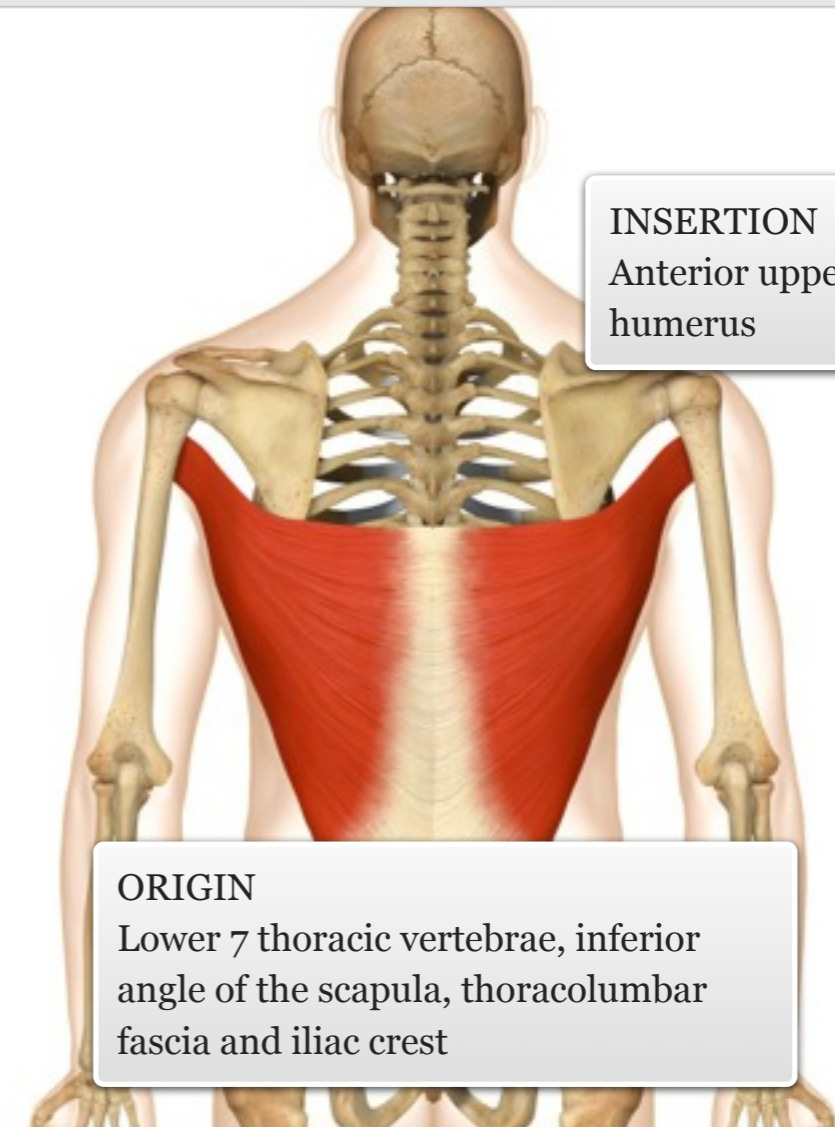


Cardio: swimming (front
crawl), Nordic walking
Resistance: lat pull down,
chin ups, pullover
Power: front somersault
(gymnastics), throwing a ball

Gym

The latissimus dorsi is the largest muscle of the back, and a powerful extensor of the shoulder. Both ends of the muscle are difficult to isolate, but the middle portion is relatively easy to palpate.

MUSCLE ACTIONS: Extension, adduction and internal rotation of the shoulder



INSERTION
Anterior upper
humerus

ORIGIN
Lower 7 thoracic vertebrae, inferior
angle of the scapula, thoracolumbar
fascia and iliac crest

level || knowledge

facts

muscle



Teres major

Audio: Teres major



Walking with crutches
Rope climbing
Paddling a canoe

Daily
Use

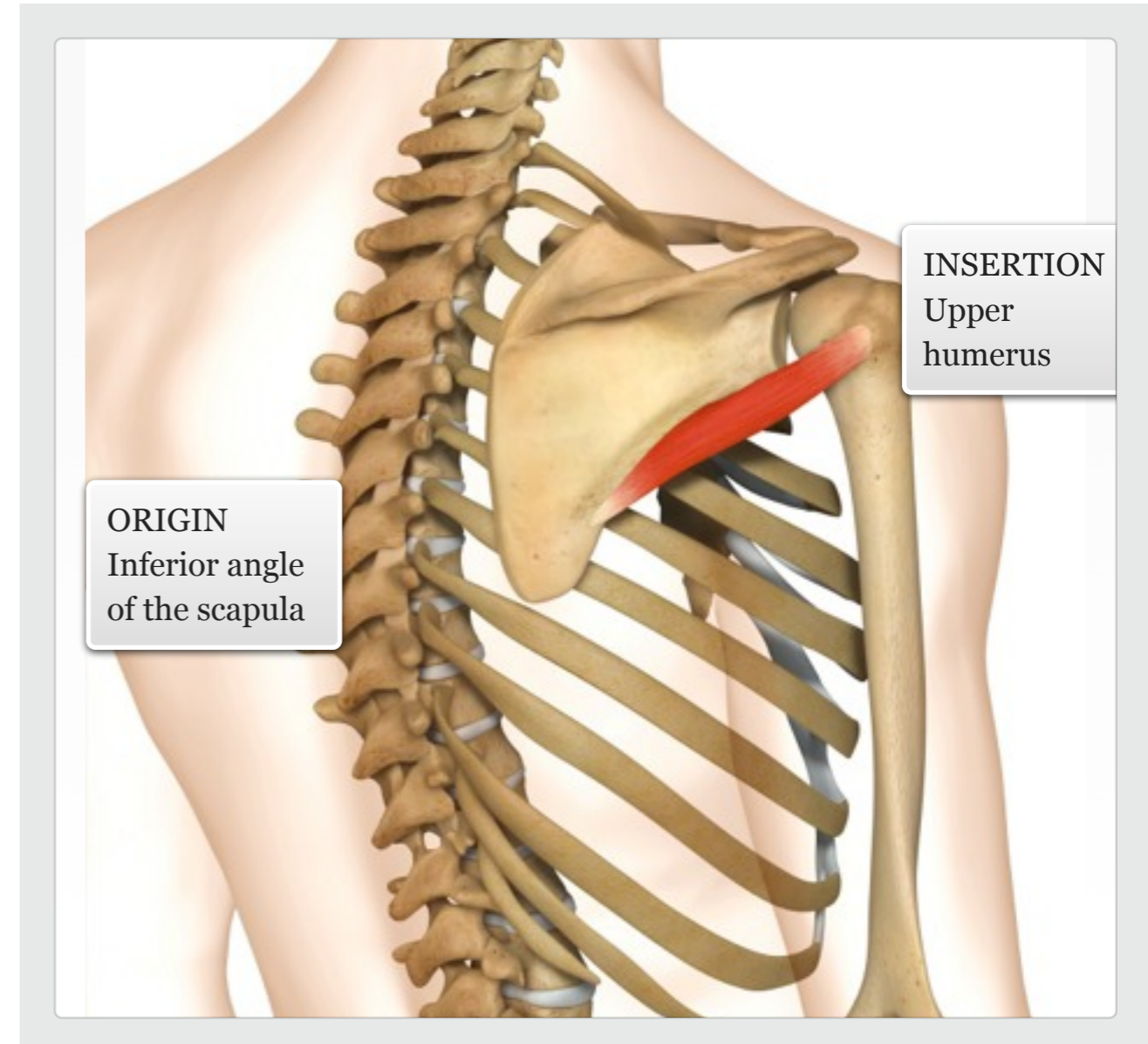
The teres major is regarded as the 'little brother' of the latissimus dorsi, because it functions as a complete synergist. Being a superficial muscle along the lateral border of the scapula, it is easy to palpate.

MUSCLE ACTIONS: Extension, adduction and internal rotation of the shoulder



Cardio: swimming (front crawl), Nordic walking
Resistance: lat pull down, chin ups, shoulder medial rotation
Power: front somersault (gymnastics), throwing a ball

Gym



ORIGIN
Inferior angle
of the scapula

INSERTION
Upper
humerus

level || knowledge

facts

muscle



Rotator cuff group

Part 1

Audio: Rotator cuff group Part 1



Reaching up to touch the ceiling (supraspinatus)

Fanning your face when hot (infraspinatus/teres minor)

Reaching round to scratch your back (subscapularis)

Daily Use



N/A

Gym

Supraspinatus

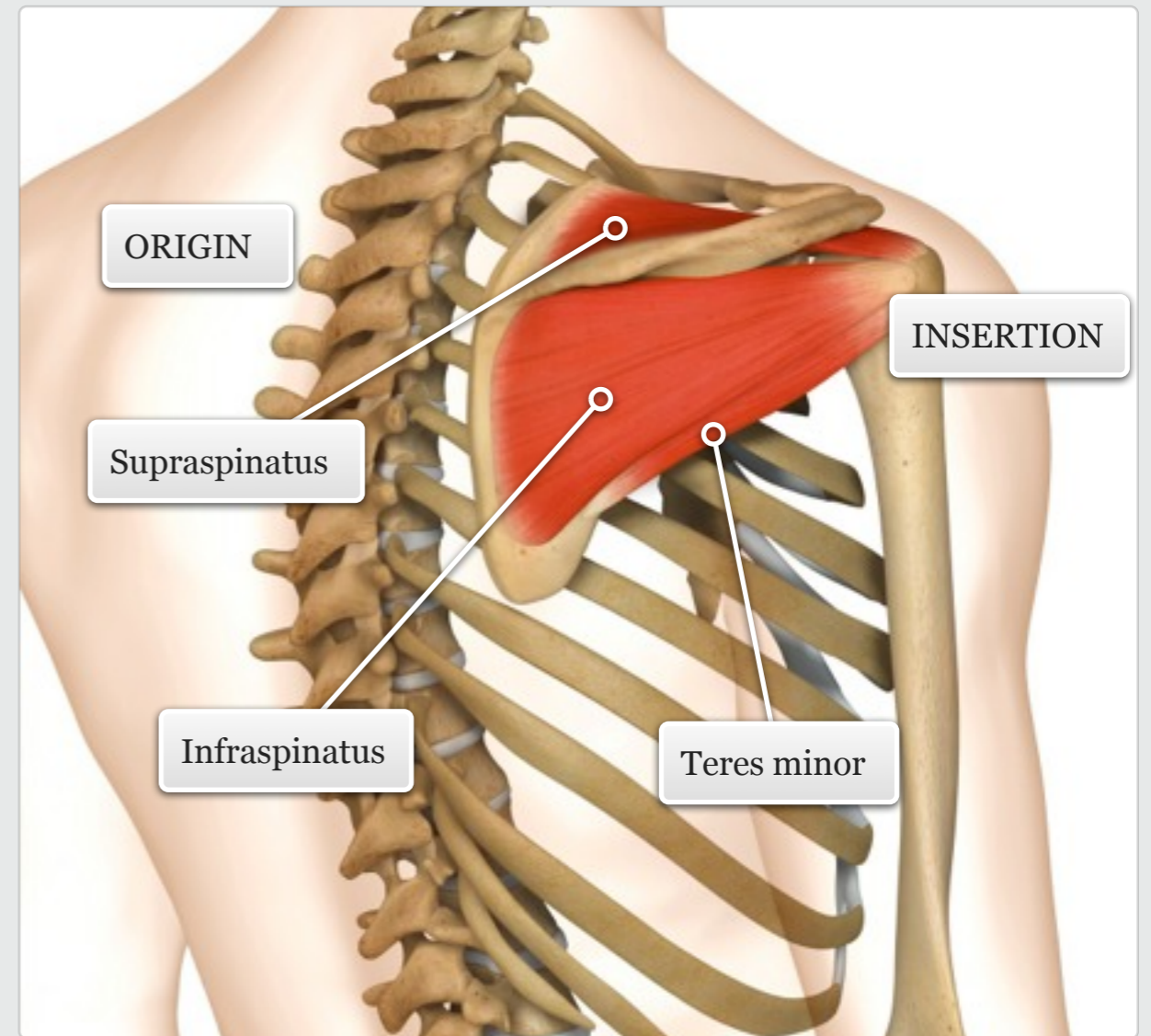
Infraspinatus

Teres minor

Subscapularis

The supraspinatus, infraspinatus, teres minor and subscapularis (rotator cuff) encompass and stabilise the glenohumeral joint. The supraspinatus is a chunky muscle lying in the supraspinous fossa deep to the upper trapezius. The flatter infraspinatus is located in the infraspinous fossa, with most of its belly being superficial. The teres minor is a smaller muscle positioned between the infraspinatus and teres major. The deeply positioned subscapularis is located on the anterior surface of the scapula.

facts



muscle

level || knowledge



Rotator cuff group

Part 2

Audio: Rotator cuff group Part 2



Reaching up to touch the ceiling (supraspinatus)

Fanning your face when hot (infraspinatus/teres minor)

Reaching round to scratch your back (subscapularis)

Daily Use



N/A

Gym

level ||| knowledge

Supraspinatus

Infraspinatus

Teres minor

Subscapularis

The supraspinatus, infraspinatus, teres minor and subscapularis (rotator cuff) encompass and stabilise the glenohumeral joint. The supraspinatus is a chunky muscle lying in the supraspinous fossa deep to the upper trapezius. The flatter infraspinatus is located in the infraspinous fossa, with most of its belly being superficial. The teres minor is a smaller muscle positioned between the infraspinatus and teres major. The deeply positioned subscapularis is located on the anterior surface of the scapula.

facts

INSERTION

ORIGIN

Subscapularis

muscle



Supraspinatus

Audio: Supraspinatus



Reaching up to touch the ceiling (supraspinatus)

Fanning your face when hot (infraspinatus/teres minor)

Reaching round to scratch your back (subscapularis)

Daily Use



Cardio: swimming

Resistance: shoulder external rotation, lateral raise

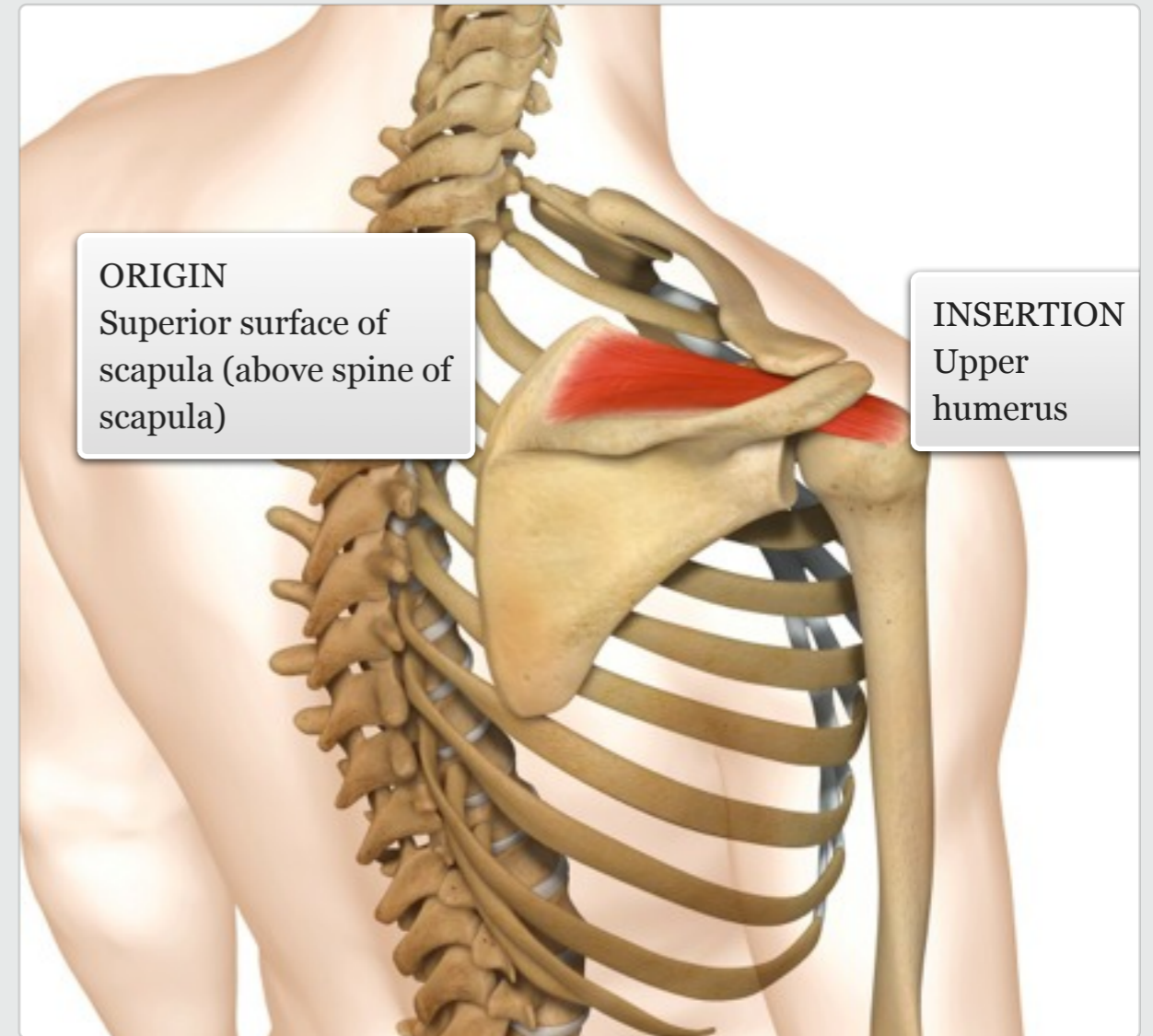
Power: throwing movements

Gym

level ||| knowledge

MUSCLE ACTIONS: Abduction and stabilisation of the shoulder joint

facts



muscle



Infraspinatus

Audio: Infraspinatus



Reaching up to touch the ceiling (supraspinatus)

Fanning your face when hot (infraspinatus/teres minor)

Reaching round to scratch your back (subscapularis)

Daily Use



Cardio: swimming, rowing

Resistance: shoulder external rotation, lateral raise

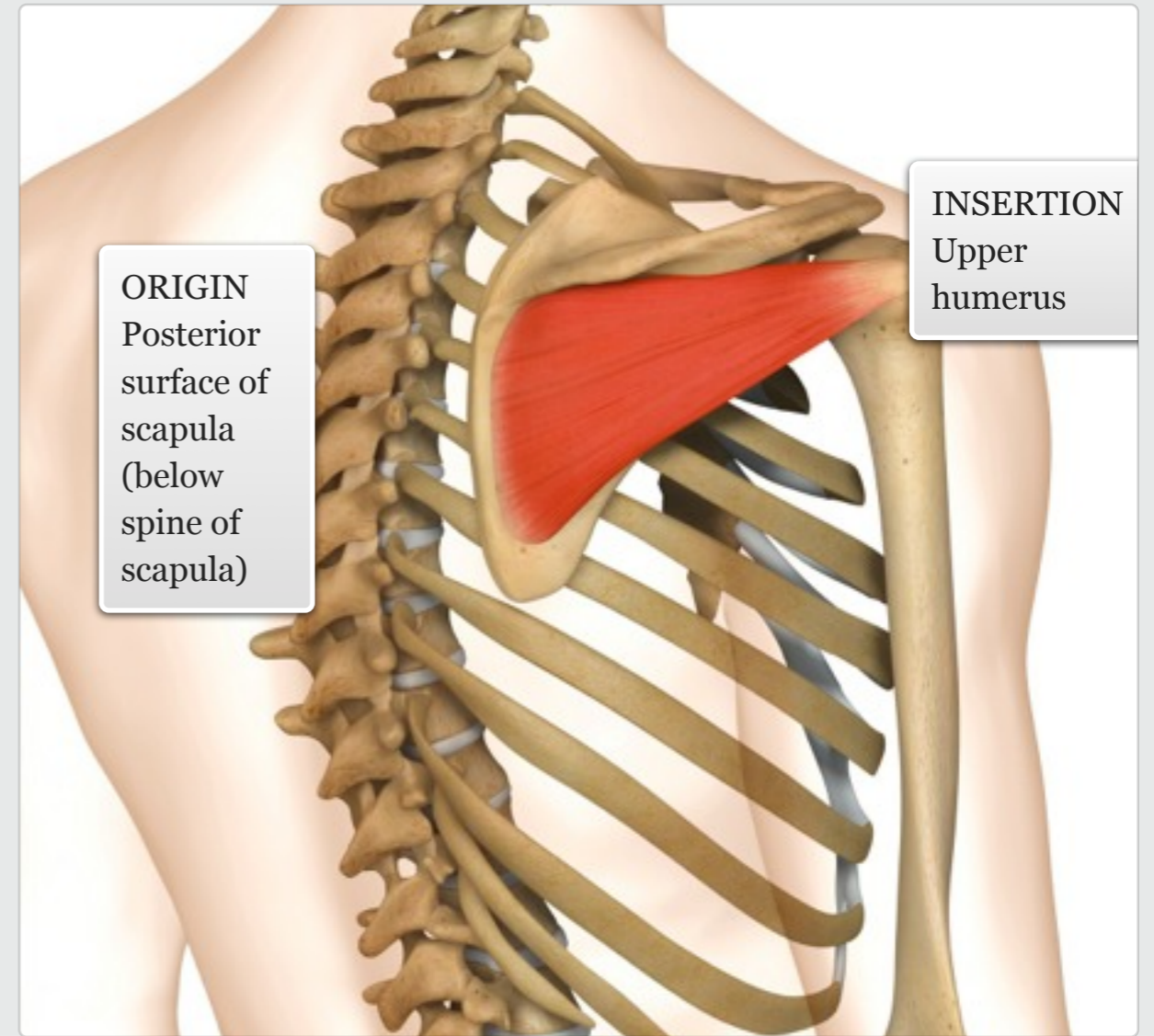
Power: throwing movements

Gym

level ||| knowledge

MUSCLE ACTIONS: External rotation, abduction, horizontal extension and stabilisation of the shoulder joint

facts



muscle



Teres minor

Audio: Teres minor



Reaching up to touch the ceiling (supraspinatus)
Fanning your face when hot (infraspinatus/teres minor)
Reaching round to scratch your back (subscapularis)

Daily Use



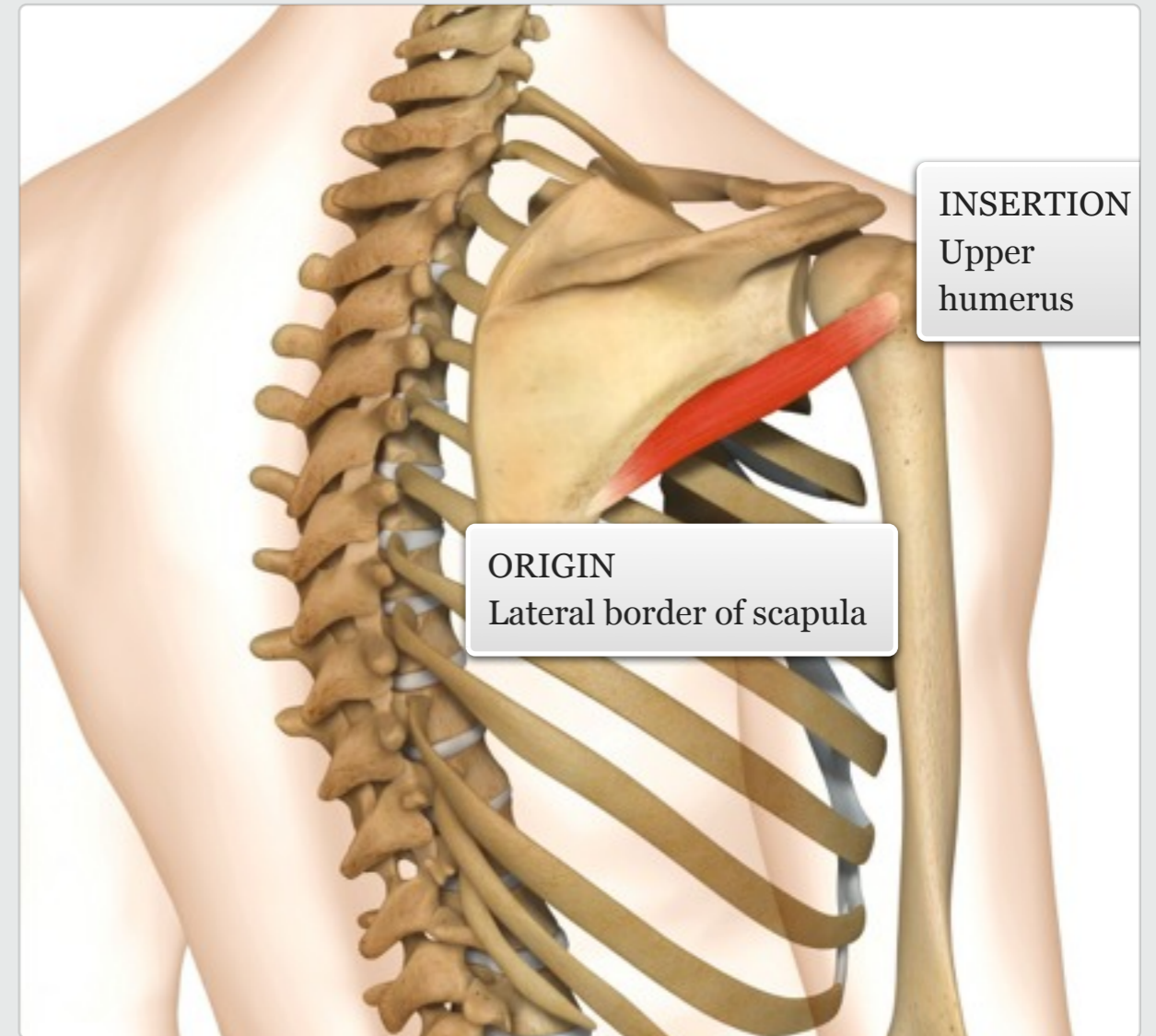
Cardio: swimming, rowing
Resistance: shoulder external rotation, lateral raise
Power: throwing movements

Gym

level ||| knowledge

MUSCLE ACTIONS: External rotation, abduction and stabilisation of the shoulder joint

facts



muscle



Subscapularis

Audio: Subscapularis



Reaching up to touch the ceiling (supraspinatus)
Fanning your face when hot (infraspinatus/teres minor)
Reaching round to scratch your back (subscapularis)

Daily
Use



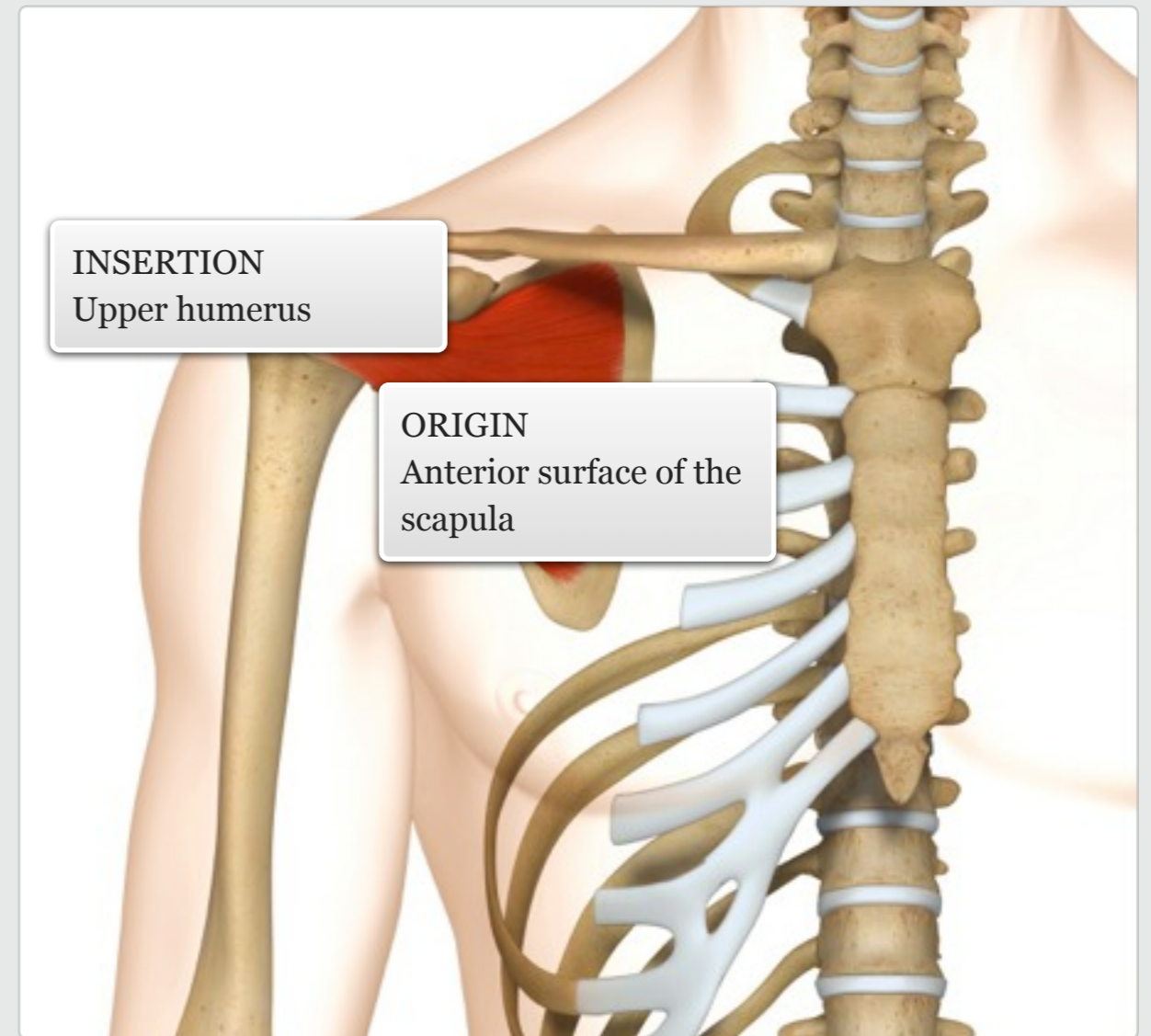
Cardio: swimming, rowing
Resistance: shoulder internal rotation, diagonal extension
Power: throwing movements

Gym

level ||| knowledge

MUSCLE ACTIONS: Internal rotation, adduction and stabilisation of the shoulder joint

facts



muscle



Deltoid

Audio: Deltoid



Almost any movement that involves the shoulder

Reaching out to shake someone's hand

Lifting a drink to your mouth

Daily Use



Cardio: rowing, swimming, cycling, running, cross-trainer

Resistance: lateral raise, shoulder press, push up

Power: throwing, punching, cartwheel, clean and jerk

Balance: side bridge, handstand, Crane pose in yoga

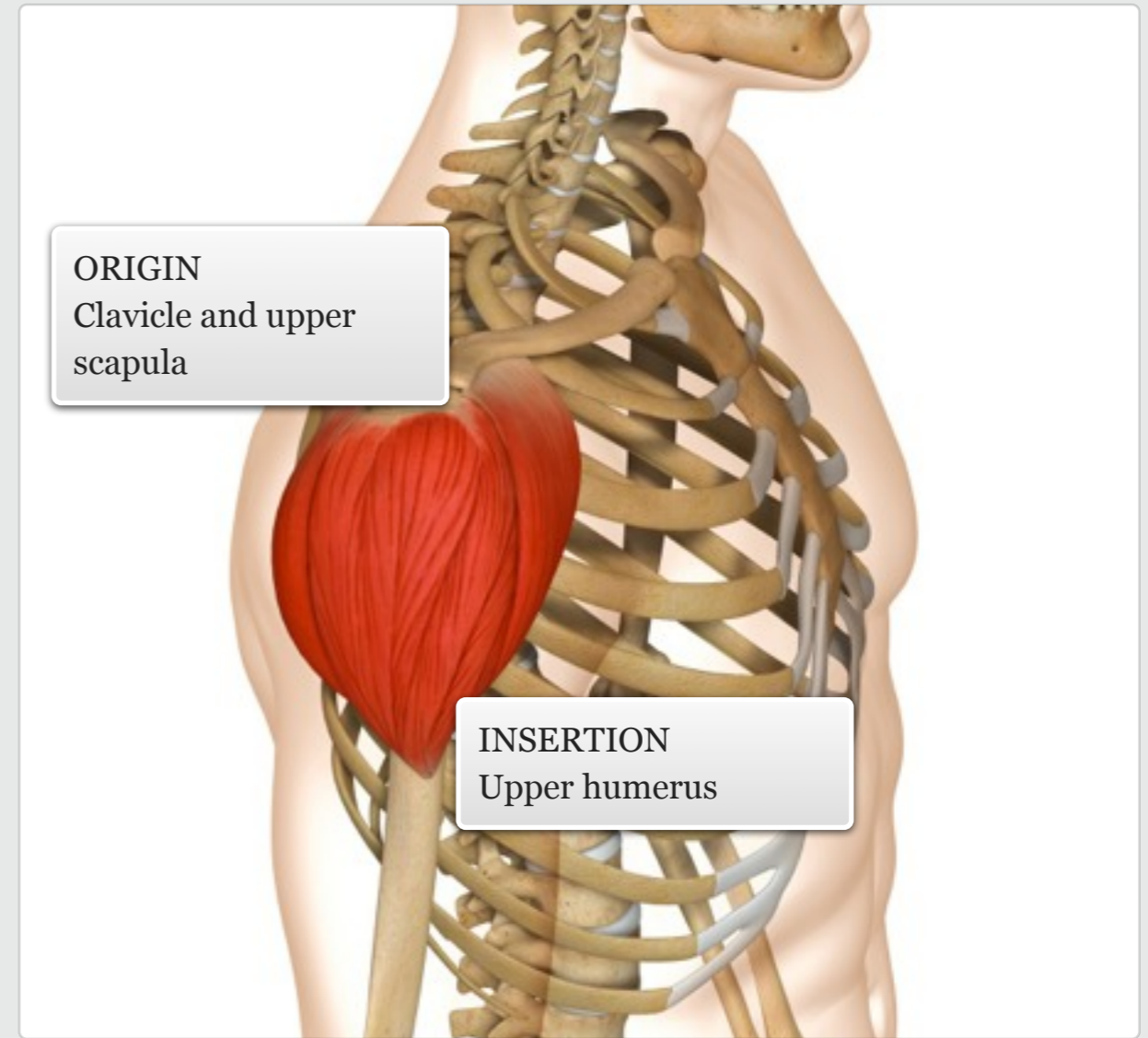
Gym

The deltoid is a triangular-shaped muscle that surrounds the shoulder joint. Its fibres can be divided into three groups – anterior, middle and posterior fibres – all of which are easy to palpate.

MUSCLE ACTIONS: Abduction, flexion and extension, horizontal flexion and extension, internal and external rotation of the shoulder.

ORIGIN
Clavicle and upper scapula

INSERTION
Upper humerus



level || knowledge

facts

muscle



Serratus anterior

Audio: Serratus anterior



Pushing open a door
Reaching to open a window

Daily
Use



Cardio: swimming
Resistance: push up, bench
press, pullover
Power: throwing, swinging
and punching movements

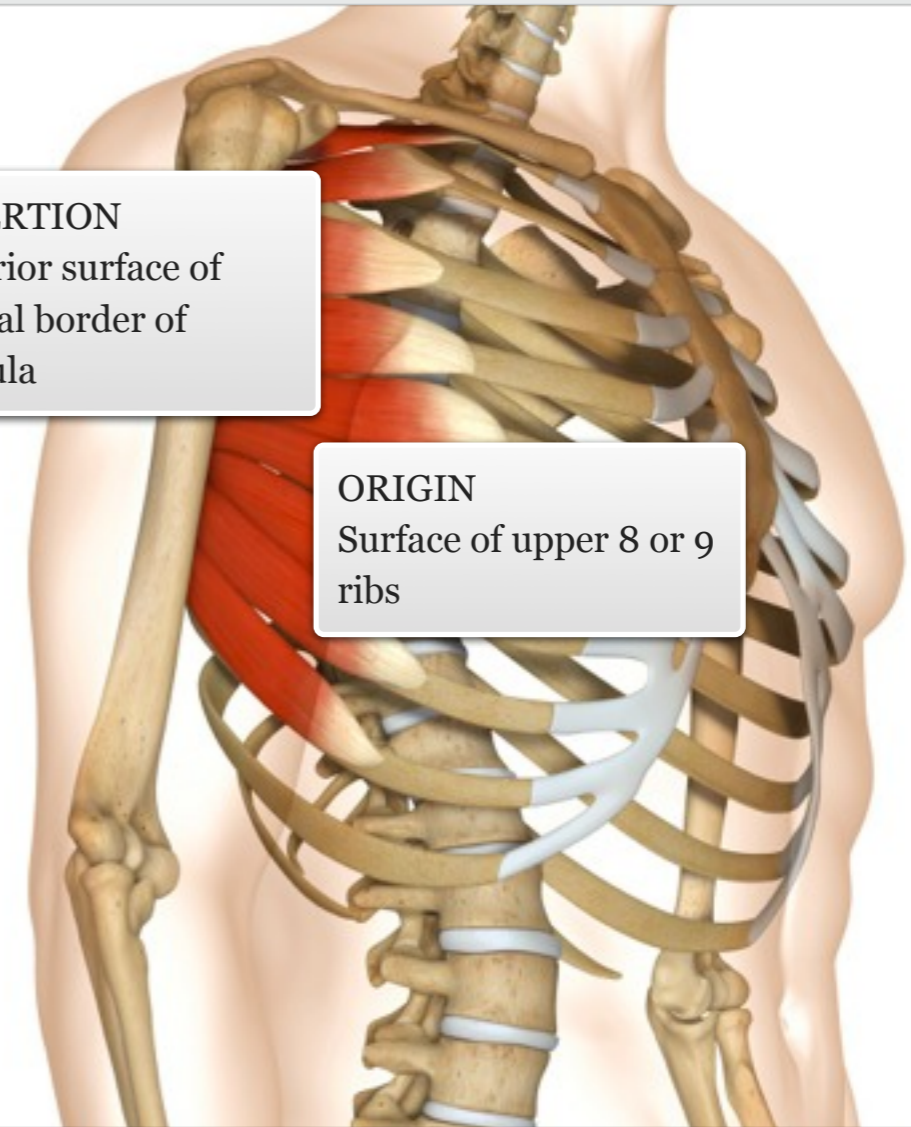
Gym

The serratus anterior lies along the posterior-lateral ribcage, and is often referred to as the 'superhero' muscle. Its fibres extend from the ribs to the medial border of the scapula. The muscle is unique in its ability to abduct the scapula (antagonistic to the rhomboids).

MUSCLE ACTIONS: Protraction of
scapula

INSERTION
Anterior surface of
medial border of
scapula

ORIGIN
Surface of upper 8 or 9
ribs



level || knowledge

facts

muscle



Pectoralis major

Audio: Pectoralis major



Pushing open a door
Sawing a piece of wood
Using a roll-on deodorant

Daily
Use

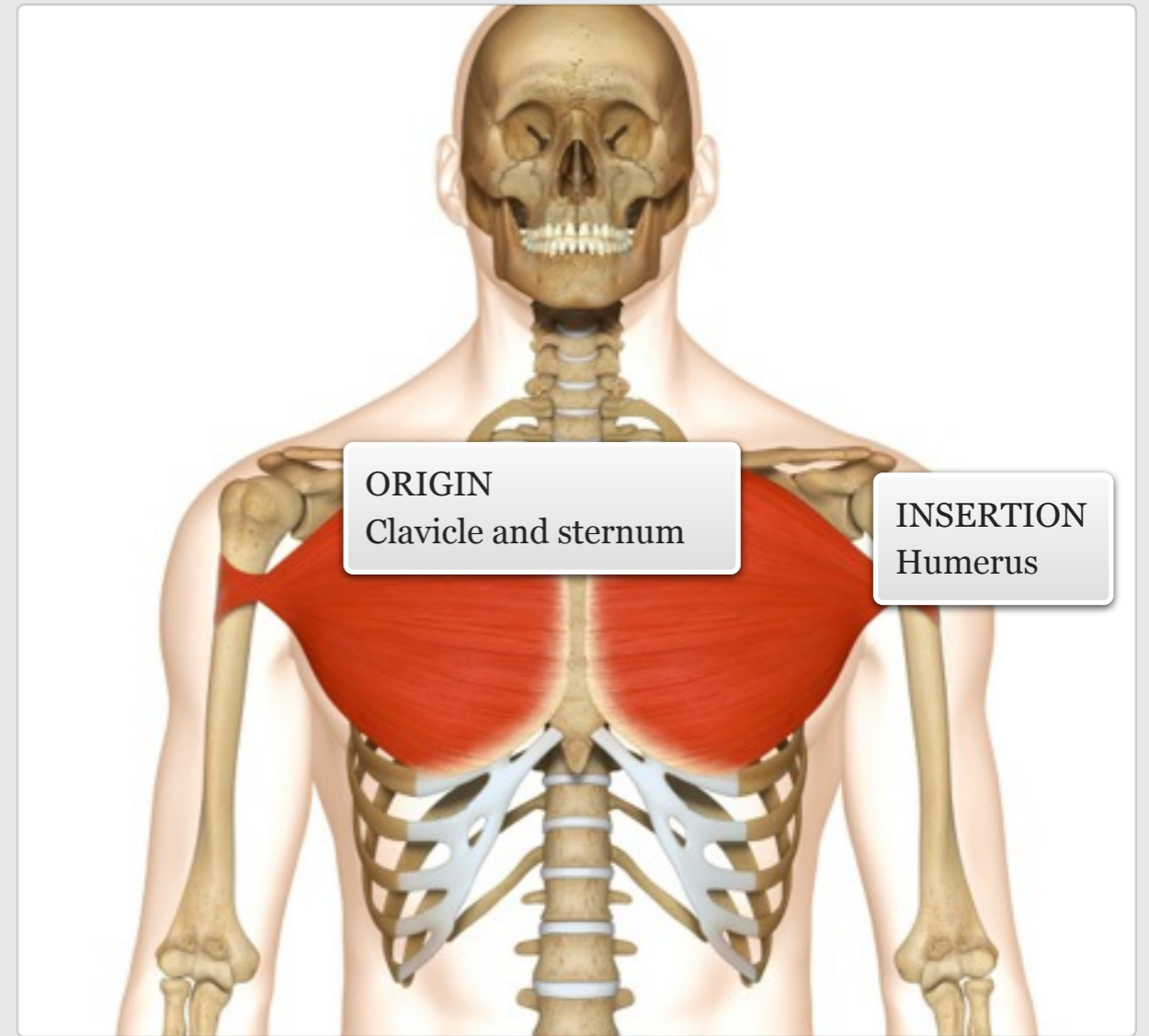
The pectoralis major is a large powerful muscle that fans across the chest. Its fibres are easily accessible and are divided into three segments – the clavicular, sternal and costal fibres.

MUSCLE ACTIONS: Flexion, horizontal flexion, adduction and internal rotation of the shoulder.



Cardio: swimming
Resistance: push up, bench press, pec flye
Power: throwing and punching movements

Gym



level || knowledge

facts

muscle



Pectoralis minor

Audio: Pectoralis minor



Pushing open a door
Reaching into a deep front pocket
Taking a deep breath

Daily Use



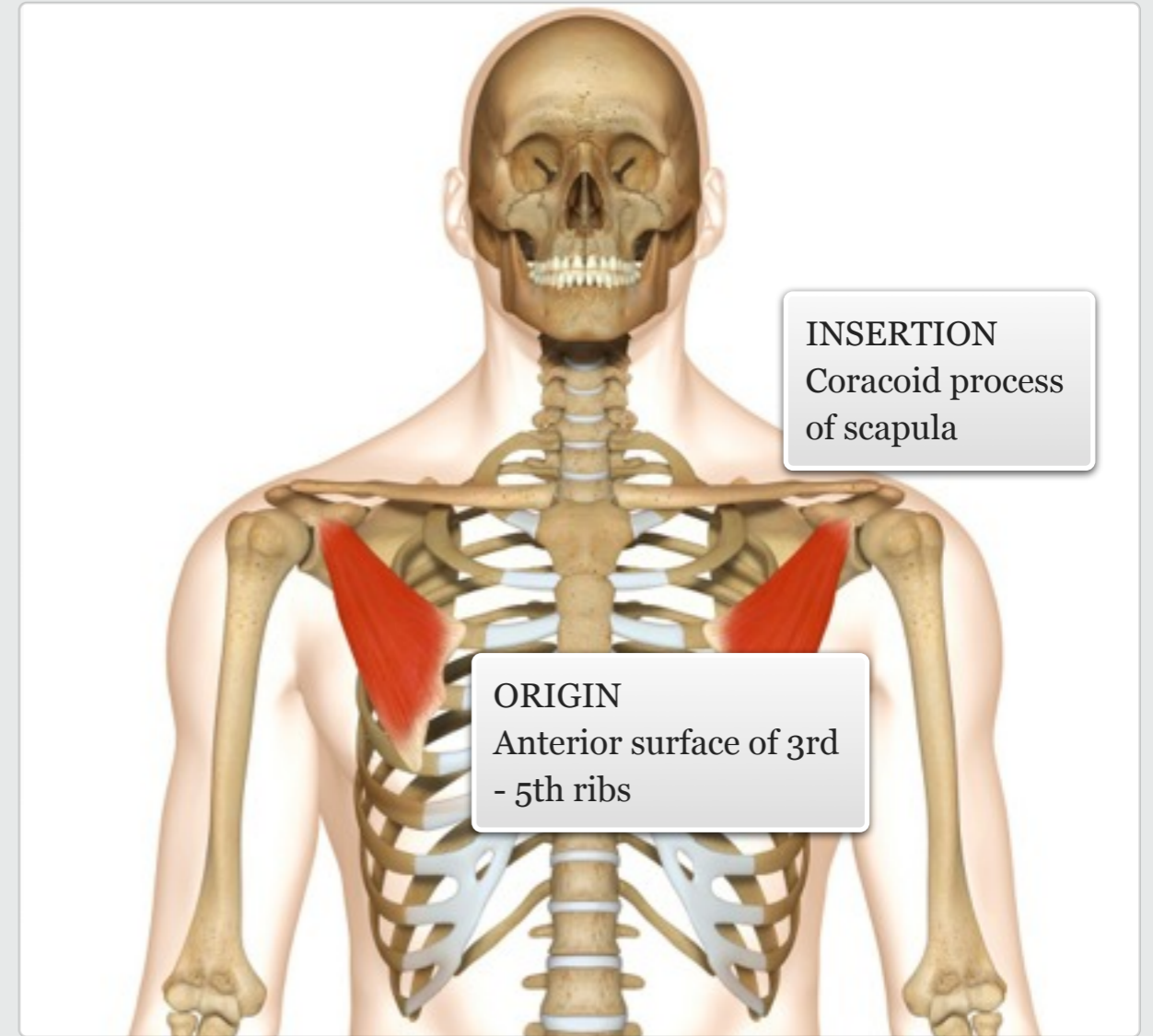
Cardio: swimming; elevates rib cage during any aerobic activity
Resistance: push up, bench press, pec flye
Power: throwing and punching movements

Gym

The pectoralis minor is the smaller of the two pectoral muscles and lies deep to the pectoralis major. It works with the serratus anterior to abduct the scapula. The muscle is best accessed by sliding underneath the thick pectoralis major.

MUSCLE ACTIONS: Depression and protraction of the scapula.

facts



muscle

level || knowledge



Biceps brachii

Audio: Biceps brachii



Picking up a shopping bag
Using a screwdriver
Carrying a child

Daily
Use

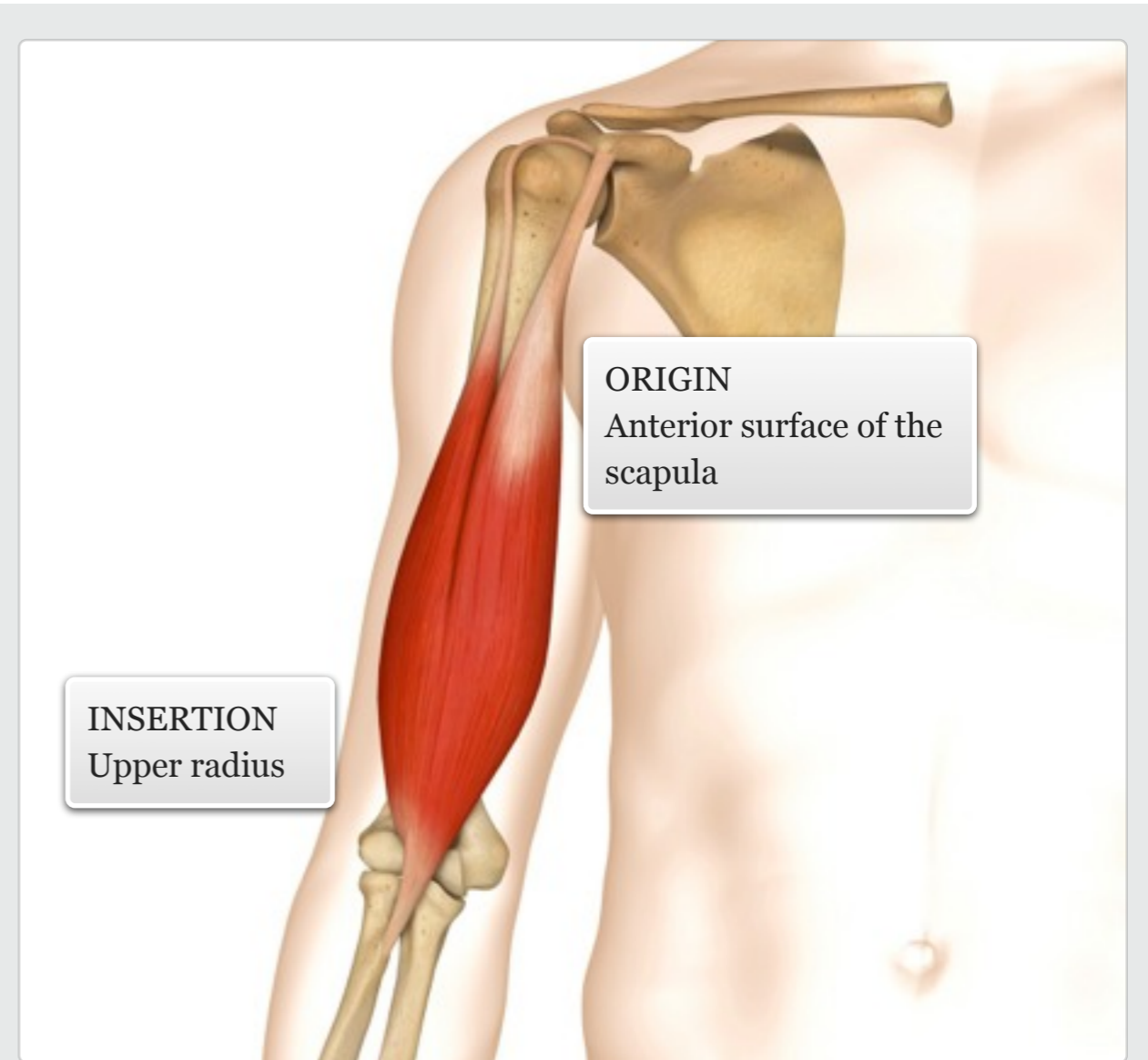


Cardio: rowing
Resistance: biceps curl, chin
up
Power: throwing, swinging
and punching movements

Gym

The biceps brachii is a superficial muscle on the anterior surface of the arm. It has a short head and a long head which merge to form a prominent belly.

MUSCLE ACTIONS: Flexion of the elbow, supination of the forearm, flexion of the shoulder.



level || knowledge

facts

muscle



Coracobrachialis

Audio: Coracobrachialis



Reaching round to scratch
your opposite ear
Protecting your face

Daily
Use



Cardio: swimming, running
Resistance: push up, bench
press
Power: throwing, swinging,
punching and blocking
movements

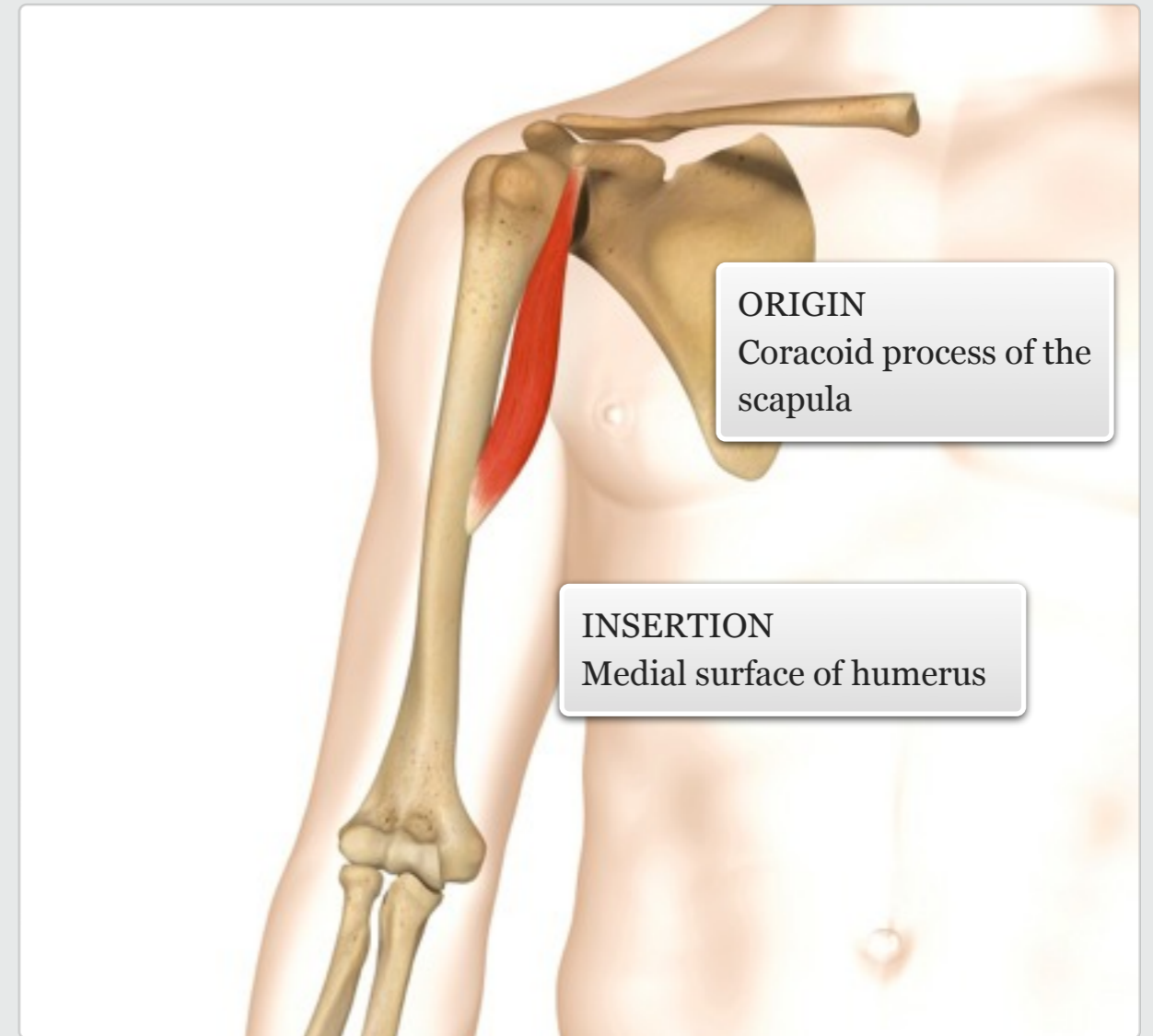
Gym

additional + knowledge

The coracobrachialis is a small slender muscle located at the upper medial part of the arm. It is deep to the pectoralis major and anterior deltoid, but becomes palpable when the shoulder is abducted.

MUSCLE ACTIONS: Flexes and adducts the shoulder

facts



muscle



Brachialis

Audio: Brachialis



Picking up a box
Carrying a child's car seat
Bringing food to your mouth

Daily
Use



Cardio: swimming (breast
stroke), rowing
Resistance: biceps curl, chin
up
Power: throwing, tennis
strokes, grappling

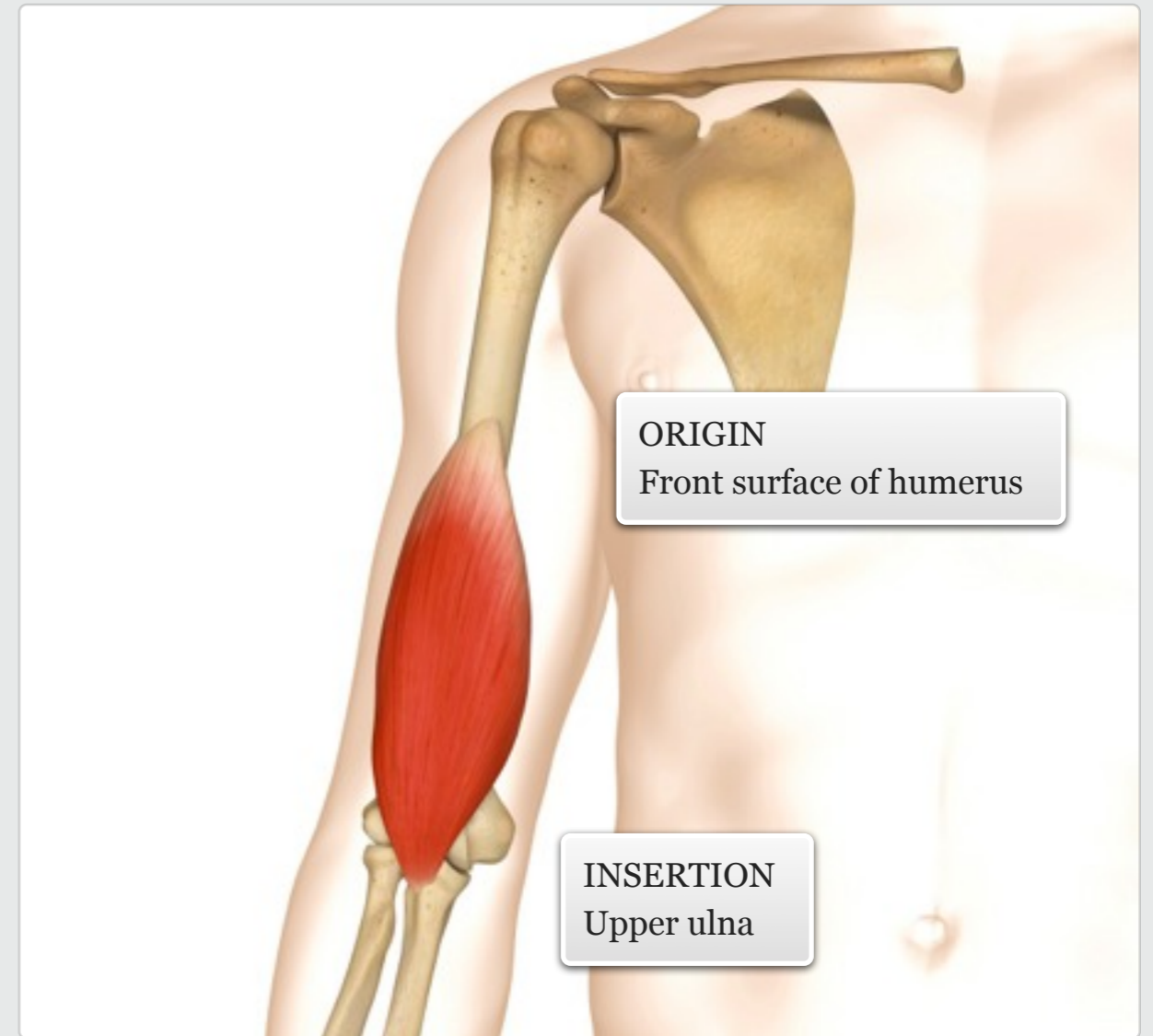
Gym

additional + knowledge

The brachialis is the only true flexor of the elbow, and lies deep to the biceps brachii. Its lateral fibres, between the biceps and triceps, are easy to palpate.

MUSCLE ACTIONS: Flexes the elbow

facts



muscle



Brachioradialis

Audio: Brachioradialis



Using a screwdriver or
corkscrew
Whisking eggs

Daily
Use



Cardio: swimming (breast
stroke), rowing
Resistance: biceps curl
(reverse grip), chin up
Power: throwing, tennis
strokes, grappling

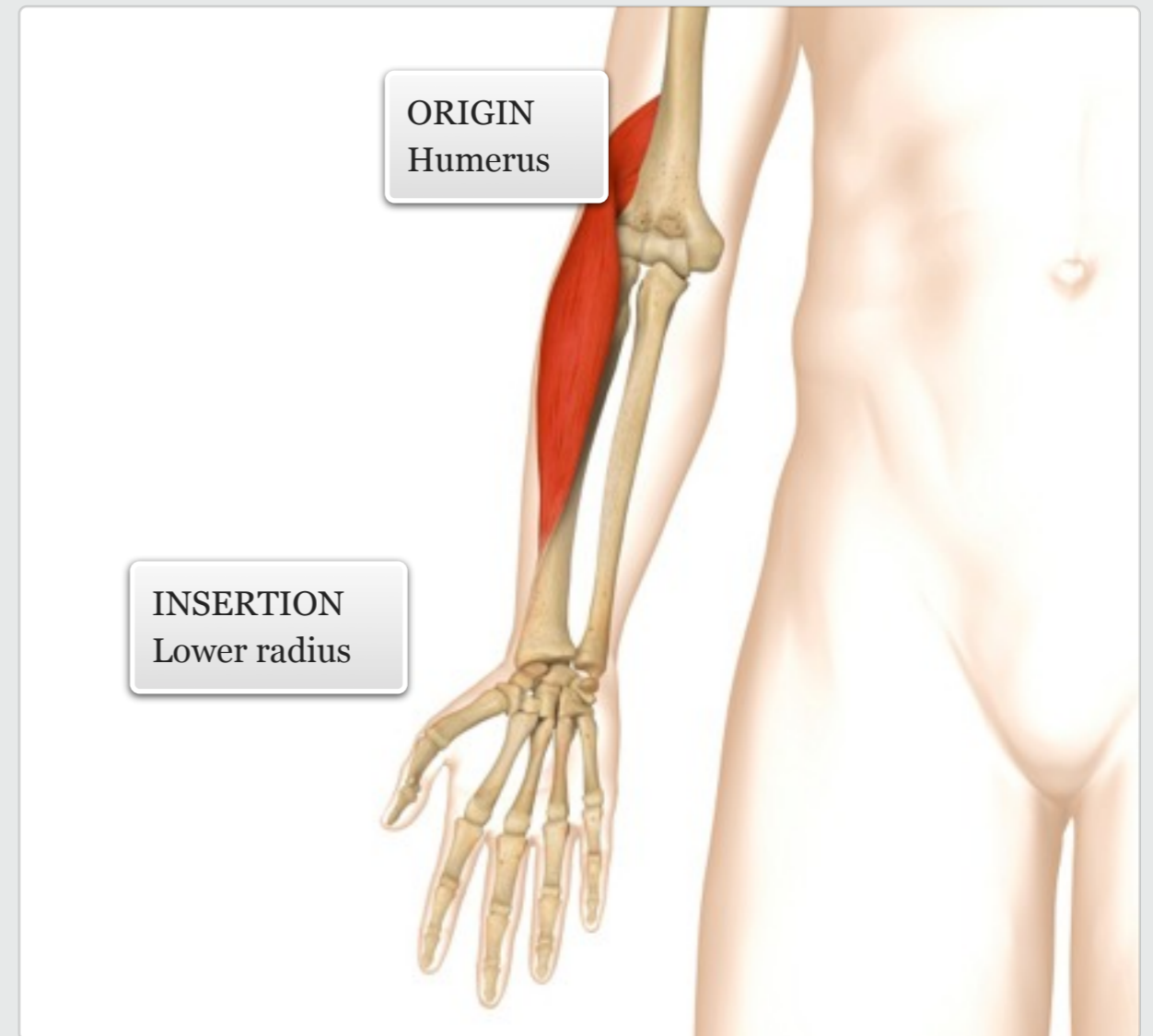
Gym

additional + knowledge

The brachioradialis is a long superficial muscle on the lateral side of the forearm. It runs the entire length of the forearm and its fibres visibly protrude when contracted.

MUSCLE ACTIONS: Flexes the elbow; assists to pronate and supinate the forearms.

facts



muscle



Triceps brachii

Audio: Triceps brachii



Pushing a door closed
Closing the boot of a car
Hammering nails

Daily
Use

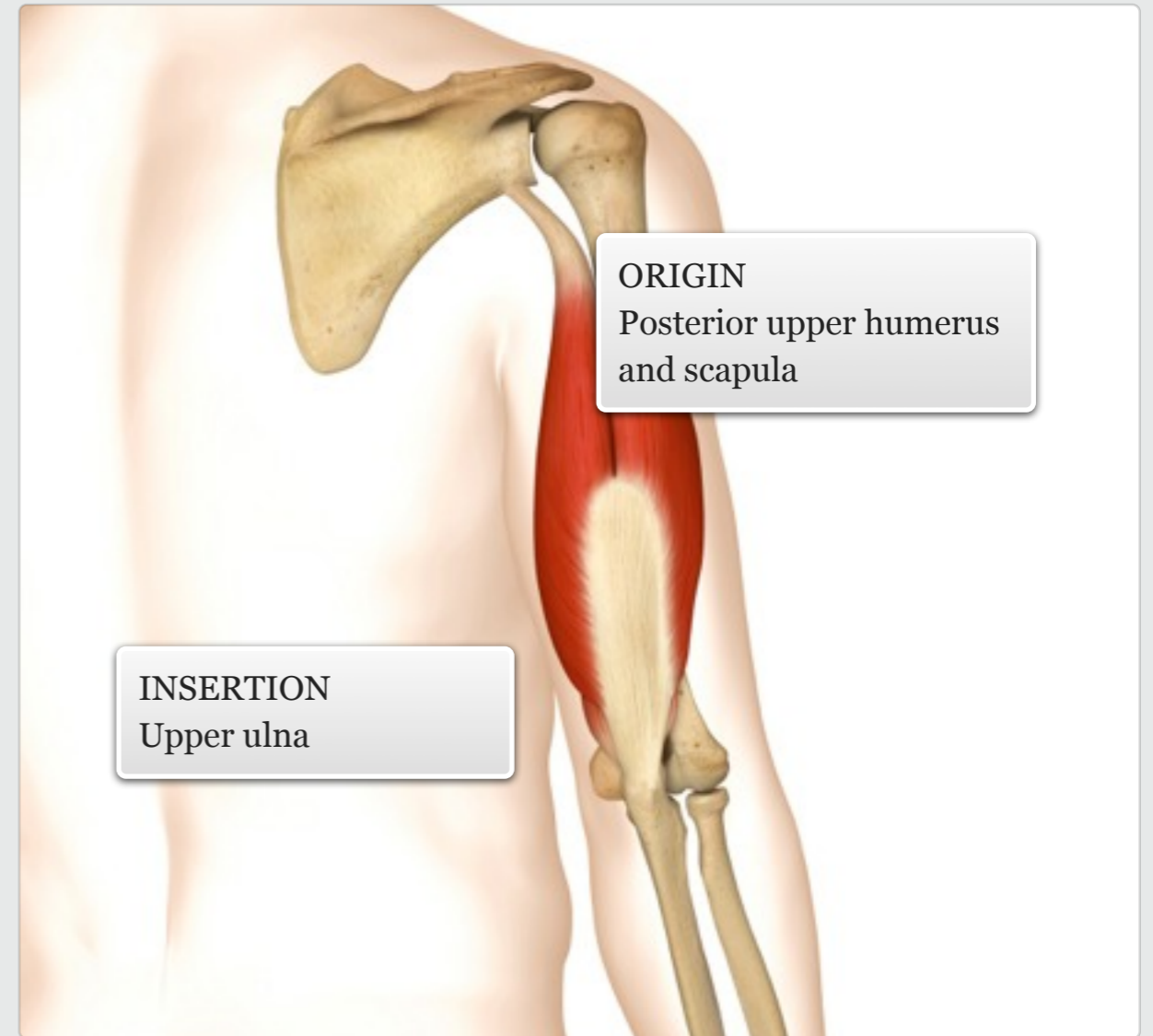


Cardio: swimming, cycling
(out of seat)
Resistance: triceps extension,
push up, dips
Power: throwing and
punching movements

Gym

The triceps brachii is the only muscle located on the posterior side of the arm. It is made up of three superficial heads – long, lateral and medial – all of which are easily accessible.

MUSCLE ACTIONS: Extension of elbow, extension and abduction of shoulder.



level || knowledge

facts

muscle

